7th moip

Athens, Greece
September 3-5, 2021
Wyndham Grand Hotel

# Face Oriented Orthodontics

## 7th Mediterranean Orthodontic Congress

www.moip2021.com

## 16th Panhellenic Orthodontic Congress

WITH THE COLLABORATION OF:

GREEK ASSOCIATION FOR ORTHODONTIC STUDY & RESEARCH

Ορθοδοντική Εταιρεία Κύπρου
CYPRUS ORTHODONTIC SOCIETY

GOAS
GREEK ORTHODONTIC ALIGNER SOCIETY

# Τα νέα standards στη συγκόλληση

® Reliance

**GoTo®**


Φωτοπολυμεριζόμενη ρητίνη

**Assure Plus®** **Assure®**


Συγκολλητικοί παράγοντες για όλες τις επιφάνειες

# Προηγμένες λύσεις για Lingual Retainers

**Ortho-Flextech™**


Αλυσίδα St. Steel, Gold


**Bond•a•Braid**


Πολύκλωνο πεπλατυσμένο

**Retainium™**


Τιτάνιο πεπλατυσμένο

**Flow Tain™**

Ρευστή φωτοπολυμεριζόμενη ρητίνη

Uni dent

**ΚΩΝ. Ι. ΤΖΙΒΕΛΕΚΑΣ**

**Αντιπροσωπείες Ορθοδοντικών Ειδών**

Γράμμου 40, 152 35 Βριλήσσια

Τηλ: 210 6858070, Fax: 210 6858099, info@ktzivelekas.gr, www.ktzivelekas.gr

# 7th Mediterranean Orthodontic Congress

# 16th Panhellenic Orthodontic Congress

## «Face Oriented Orthodontics»

Athens
Wyndham Grand Hotel

3 - 5 September
2021
PROGRAMME

Under the Auspices
of the Ministry of Health
& Dental Society of Athens

Dental CE credits are given

- Congress 3-5/9/2021: 15 CE credits
- Attendees based outside Athens: 1 CE credit plus

With the collaboration of the
Cyprus Orthodontic Society,
Greek Society of Lingual Orthodontics &
the Greek Orthodontic Aligner Society

GREEK ASSOCIATION FOR ORTHODONTIC STUDY & RESEARCH

ΕΛΛΗΝΙΚΗ ΕΤΑΙΡΕΙΑ ΓΛΩΣΣΙΚΗΣ ΟΡΘΟΔΟΝΤΙΑΣ
GREEK SOCIETY OF LINGUAL ORTHODONTICS

GOAS
GREEK ORTHODONTIC ALIGNER SOCIETY

Ορθοδοντική Εταιρεία Κύπρου
CYPRUS ORTHODONTIC SOCIETY

# ORTHOSHOP E.E.

GC Orthodontics

GLOBAL EXPERTS IN ORTHODONTICS

ROYAL ORTHODONTICS

## EXPERIENCE
mini metal Rhodium Coated

Αισθητικό άγκιστρο με επικάλυψη ροδίου

## EXPERIENCE
ceramic

Αυτόδετο κεραμικό άγκιστρο
της GC Orthodontics



## LEGEND

Άγκιστρα κατασκευασμένα
με CNC milled slot για
ακρίβεια διαστάσεων

## Chic.

Κεραμικό άγκιστρο της
GC Orthodontics

## GC Ortho **Connect**™

Μοναδική κόλλα για brackets
χωρίς την χρήση Primer

## GC Ortho **Connect**™ **Flow**

Μοναδική κόλλα για lingual retainer
χωρίς την χρήση Primer

## psm
MEDICAL SOLUTIONS

## TADmatch™

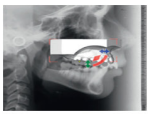

powered by
OnyxCeph³™

***BENEslider***, mesial/distal

Hybrid Hyrax®

"Temporary Implant"

Σπύρου Δάβαρη 67, Κορωπί 2109958506 info@orthoshop.gr

# 7th MEDITERRANEAN ORTHODONTIC CONGRESS

# 16th PANHELLENIC ORTHODONTIC CONGRESS

## Athens, September 3rd – 5th 2021

## MESSAGE FROM THE PRESIDENT

Dear friends & colleagues,

It is my great pleasure to invite you to the 7th Mediterranean Orthodontic Integration Project (MOIP) Congress, to be held in Athens, from the 3rd to the 5th of September, 2021.

The Congress is organized by the Greek Association for Orthodontic Study & Research, with the collaboration of the Greek Lingual Orthodontic Society, the Greek Orthodontic Aligners Society and the Cyprus Orthodontic Society, together with the assistance of MOIP ambassadors from Orthodontic Societies of countries in the Mediterranean region.

The main meeting theme is «Face oriented Orthodontics». The organizing committee is putting together an outstanding scientific programme that includes excellent speakers proposed by the participating countries, as well as a pre- and post-congress course, on the 3rd and 5th of September.

The Congress venue is the «Wyndham Grand Hotel», situated in the centre of Athens, with easy access to the historical and cultural sites of this great city. September is probably the best season to visit Athens. The Congress will be a great opportunity to extend and even expand your stay, to experience the beauty of the Greek islands or the mainland.

The 7th MOIP Congress will be a new occasion to strengthen the ties between the countries and orthodontic societies in our region and promote the goal of improving the quality of educational programmes and the standard of patient's care.

I look forward to seeing you in Athens for an unforgettable experience.

Prof. Demetrios Halazonetis

Head of the Orthodontic Dept. of National & Kapodistrian University of Athens

# PROGRAMME AT A GLANCE

## PRE-CONGRESS SEMINAR

**Friday, September 3rd, 2021**

**Dr. David Sarver**
Esthetics for a Lifetime-Discover the keys

08.00 - 08.45 Registration

**Morning Session** Chairpersons: Basdra E. - Boulouchou Our.
08.45 - 09.00 Introductory remarks - Speaker Presentation
09.00 - 10.45 Esthetics for a Lifetime-Discover the keys - Part 1

10.45 - 11.15 Coffee break - visit at the exhibition area

**Mid-day Session** Chairpersons: Theodorakopoulou L. - Medawar L.
11.15 - 12.45 Esthetics for a Lifetime-Discover the keys - Part 2

12.45 - 13.30 Lunch
13.30 - 14.30 Esthetics for a Lifetime-Discover the keys - Part 3

## CONGRESS

**Saturday, September 4th, 2021**

08.30 - 09.00 Registration

08.45 - 09.00 Introductory remarks AAO President Dr. K. Dillehay, honorary GAOSR member Em. Prof M. Spyropoulou, & 7th MOIP President Prof. D. Halazonetis.

### ATHINA ROOM

**Session 1** Chairpersons: Abbas Z. - Karakousoglou S.
09.00 - 09.45 **Dr. David Sarver**
Contemporary Concepts in Esthetic Treatment Design in Orthodontics
09.45 - 10.15 **Prof. Letizzia Perillo**
CLP Face Oriented Orthodontics
10.15 - 10.45 **Prof. Khaled Aboulazm**
A face-driven biomechanical way out for the management of impacted and transposed teeth
10.45 - 11.15 **Prof. Christos Katsaros**
With the face in mind does orthodontic tooth movement induce the development of gingival recession?

11.15 - 11.45 Exhibition visit - Coffee break

**Session 2** Chairpersons: Halazonetis D.- Perillo L.
11.45 - 12.15 **Prof. Effie Basdra**
How do we move teeth after all? An up-to-day biological insight
12.15 - 12.45 **Prof. Nikhilesh Vaid**
Artificial Intelligence Driven Orthodontics: A quest for utopia?
12.45 - 13.15 **Prof. Josef Ghafari**
Facial esthetics in the eyes of the orthodontic therapeutic potentials and limitations

13.15 - 14.30 Break

# PROGRAMME AT A GLANCE

**Session 3** Chairpersons: Sofroniou G. - Maroulakos M.

14.30 - 15.15 **Dr. Chad Foster**
Everyday Esthetics - 45 clinical tips in 45 minutes

15.15 - 16.45 **Dr. Raffaele Spena**
Complex Cases - Solutions utilizing revisited diagnostic and biomechanical protocols
With the kind sponsorship of M. VITSAROPOULOS

16.45 - 17.30 **Dr. Chad Foster**
Best practices for Non-extraction approach to "Borderline" orthodontic cases
With the kind sponsorship of IOANNIS TSAPRAZIS SA-RMO

## HERA ROOM
## DOCTORS AND STAFF PROGRAMM

**Session 1** Chairpersons: Efstathiou E. - Spyropoulos N.

09.00 - 09.45 **Mr. Paul Gange Jr.**
Reducing bond failures on all surfaces - Part 1

09.45 - 10.15 **Assoc. Prof. William Papaioannou**
Effective oral hygiene for the orthodontic patient

10.15 - 10.45 **Mr. Panos Perros**
Digital treatments transforming lives. Facts, insights and more...

10.45 - 11.15 **Prof. Ioannis Tzoutzas**
Safety and effective disinfection in the Orthodontic clinic

11.15 - 11.45 Exhibition visit - Coffee break

**Session 2** Chairpersons: Rontogianni A. - Raisakis Th.

11.45 - 12.30 **Mr. Paul Gange Jr.**
Reducing Bond Failures On All Surfaces Part 2
With the kind sponsorship of UNIDENT - K. Tzivelekas

## DOCTORS AND STAFF PROGRAMM

12.30 - 13.00 **Prof. Stella Chaushu**
Impacted teeth - essential yet overlooked facts in diagnosis and treatment planning

13.15 - 14.30 MOIP Meeting working lunch

**Session 3** Chairpersons: Koutsoumpou D. - Nakou D.

14.30 - 15.00 **Asst. Prof. Eyas Abuhijleh**
Soft Tissue Profile Values in Palestinian Adults

15.00 - 17.30 **Oral Presentations**

20.30 - 22.00 **President´s Reception**

# PROGRAMME AT A GLANCE

**Sunday, September 5th 2021**

## ATHINA ROOM

**Session 4** Chairpersons: Cozzani M. - Vastardi E.

09.00 - 09.30 **Prof. Stella Chaushu**
Missing anterior teeth in young patients face and age oriented ortho-prosthetic treatment

09.30 - 10. 00 **Asst. Prof. Dimitrios Michelogiannakis**
Clinical interdisciplinary management of a patient with cerebral palsy, Class III malocclusion, anterior open bite and gingival overgrowth

10.00 - 10.30 **Asst. Prof. Georgios Kanavakis**
Facial esthetics: A patient-centered approach

10.30 - 11.00 **Prof. Ahmet Keles**
Improving the quality of smile with the interdisciplinary team approach

11.00 - 11.30 Exhibition visit - Coffee break

**Session 5** Chairpersons: Kardara D., Attia Kh. H.

11.30 - 12.00 **Dr. David Raickovic**
PREDICTABILITY, a key word for successful treatment plan in aligner orthodontics?
With the kind sponsorship of INVISALIGN - iTero

12.00 - 12.45 **Prof. Dr. Dieter Drescher**
Change the face! Advances in the treatment of growing Class III patients
With the kind sponsorship of ORTHOSHOP EE- ROYAL ORTHODONTICS

12.45 - 13.15 **Dr. Chris Laspos**
Face or Occlusion?
With the kind sponsorship of INVISALIGN - itero

15.15 - 15.45 Coffee break

## HERA ROOM ROOM

**Session 4** Chairpersons: Exarchou M. - Papagiannis A.

09.00 - 10.00 **Oral Presentations**

10.00 - 10.30 **Dr. Pedro Costa Monteiro**
Treating kids with aligners - My approach with Invisalign Teen & First
With the kind sponsorship of FN ORTHODONTICS

10.30 - 12.20 **Oral Presentations**

13.15 - 13.45 **Closing Ceremony**

# PROGRAMME AT A GLANCE

## POST-CONGRESS COURSE

**Sunday, September 5th 2021**

### ATHINA ROOM

Chairpersons: Damanakis G. - Douma K.

14.00 - 15.30 **Dr. David Raickovic**
PREDICTABILITY, a key word for successful treatment plan in aligner orthodontics? Part A

15.30 - 15.45 Coffee break

Chairpersons: Konstantonis D. - Stamou E.

15.45 - 17.15 **Dr. David Raickovic**
PREDICTABILITY, a key word for successful treatment plan in aligner orthodontics? Part B
With the kind sponsorship of INVISALIGN - itero

# PARTICIPANTS

**INVITED SPEAKERS**

Abuhijleh Eyas
Basdra Effie
Chaushu Stella
Drescher Dieter
Foster Chad
Gange Paul Jr.
Ghafari Josef
Kanavakis Georgios
Katsaros Christos
Keles Ahmet
Khaled Aboulazm
Laspos Chris
Michelogiannakis Dimitrios
Monteiro Pedro Costa
Papaioannou William
Perillo Letizia
Peros Panos
Raickovic David
Sarver David
Spena Raffaele
Tzoutzas Ioannis
Vaid Nikhilesh

**FREE TOPIC ORAL PRESENTATION**

Chiarenza Maria Chiara
Christopoulou Isidora
Davidovich Moshe
Douma Aikaterini
El-Bokle Dalia
Elkordy Sherif Aly Mahmoud
Elkalza Ahmed
Evangelidis Vasileios
Exarchou Fotis
Floros Yiannis
Hasan Amna
Kalia Ajit
Kassem Islam
Klein Yehuda
Nucci Ludovica
Mizrahi Gilad
Panayi Nearchos
Papadimitriou Aikaterini
Papaefthymiou Petros
Papagiannis Alexandros
Pratikaki Christina
Rotolo Rossana Patricia
Sarne Ofer
Scerra Melania Selene
Sella-Tunis Tatiana
Shahen Shereef
Shpack Nir
Sideri Sofia
Siotou Kalliopi
Zarkadi Athanasia-Eirini

**E-POSTER PRESENTATIONS**

Angelopoulos Alice
Athanasiou Maria
Christopoulou Isidora
De Simone Antonella
Doukaki Dafni
Elkalza Ahmed
Ergatoudes Andreas
Fiori Adriana
Geller Fishman Zehava
Gkeka Olga
Gratsia Sofia
Kathopoulis Ilias
Kovlakidis Alexandros
Koukou Melina
Krikonis Harris
Manoukakis Thomas
Nucci Ludovica
Papaefthymiou Petros
Rontogianni Aliki
Roulias Panagiotis
Sella Tunis Tatiana
Shahen Shereef
Siotou Kalliopi
Strangio Bruno M.
Tsironi Konstantina
Vasoglou George
Vlasiadi Eleni

Athens, September 2021
Edited & coordinated by Ourania Boulouchou & Vassileios Stathopoulos
Published by MegaPrint

# *Friday September 3rd*

## PRE-CONGRESS SEMINAR

### ATHINA ROOM

### Dr. David Sarver

*Esthetics for a Lifetime-Discover the keys*

08.00 - 08.45 Registration

**Morning Session** Chairpersons: Basdra E. - Boulouchou Ou.

08.45-09.00 Introductory remarks - Speaker Presentation

09.00 - 10.45 **Dr. David Sarver**
Esthetics for a Lifetime-Discover the keys - part 1

10.45 - 11.15 Coffee break - visit at the exhibition area

**Mid-day Session** Chairpersons: Theodorakopoulou L. - Medawar L.

11.15 - 12.45 **Dr. David Sarver**
Esthetics for a Lifetime-Discover the keys - Part 2

12.45 - 13.30 Lunch

13.30 - 14.30 **Dr. David Sarver**
Esthetics for a Lifetime-Discover the keys - Part 3

ΕΤΑΙΡΕΙΑ ΟΡΘΟΔΟΝΤΙΚΗΣ & ΓΝΑΘΟΠΡΟΣΩΠΙΚΗΣ ΜΕΛΕΤΗΣ & ΕΡΕΥΝΑΣ | GREEK ASSOCIATION FOR ORTHODONTIC STUDY & RESEARCH

# *Saturday September 4th*

## CONGRESS

### ATHINA ROOM

- Aboulazm Khaled
- Basdra Effie
- Foster Chad
- Ghafari Josef
- Katsaros Christos
- Perillo Letizzia
- Sarver David
- Spena Rafaelle
- Vaid Nikhilesh

### HERA ROOM

- Abuhijleh Eyas
- Chaushu Stella
- Gange Paul Jr.
- Papaioannou William
- Perros Panos
- Tzoutzas Ioannis

FN ORTHODONTICS

Orthodontic Services



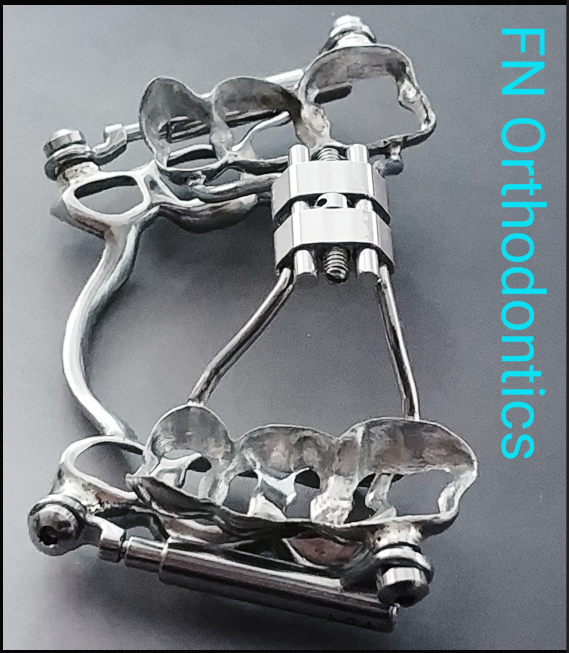


https://www.fnorthodontics.com
https://fnlab.org
info@fnlab.org
fn_orthodontics@yahoo.gr

GOING TO THE NEXT LEVEL

2-8 Tetrapoleos str. , Goudi, Athens, pc:11527
Attiki, Greee, tel: +302107773373, Whatsapp: +306982883123

# CONGRESS

**Saturday, September 4th, 2021**

08.30 - 09.00 Registration

08.45 - 09.00 Introductory remarks AAO President Dr. K. Dillehay, honorary GAOSR member Em. Prof M. Spyropoulou, & 7th MOIP President Prof. D. Halazonetis.

## ATHINA ROOM

**Session 1** Chairpersons: Abbas Z. - Karakousoglou S.

09.00 - 09.45 **Dr. David Sarver**
Contemporary Concepts in Esthetic Treatment Design in Orthodontics

09.45 - 10.15 **Prof. Letizzia Perillo**
CLP Face Oriented Orthodontics

10.15 - 10.45 **Prof. Khaled Aboulazm**
A face-driven biomechanical way out for the management of impacted and transposed teeth

10.45 - 11.15 **Prof. Christos Katsaros**
With the face in mind does orthodontic tooth movement induce the development of gingival recession?

11.15 - 11.45 Exhibition visit - Coffee break

**Session 2** Chairpersons: Halazenetıs D.- Perillo L.

11.45 - 12.15 **Prof. Effie Basdra**
How do we move teeth after all? An up-to-day biological insight

12.15 - 12.45 **Prof. Nikhilesh Vaid**
Artificial Intelligence Driven Orthodontics: A quest for utopia?

12.45 - 13.15 **Prof. Josef Ghafari**
Facial esthetics in the eyes of the orthodontic therapeutic potentials and limitations

13.15 - 14.30 Break

**Session 3** Chairpersons: Sofroniou G. - Maroulakos M.

14.30 - 15.15 **Dr. Chad Foster**
Everyday Esthetics - 45 clinical tips in 45 minutes

15.15 - 16.45 **Dr. Raffaele Spena**
Complex Cases - Solutions utilizing revisited diagnostic and biomechanical protocols
With the kind sponsorship of M. VITSAROPOULOS

16.45 - 17.30 **Dr. Chad Foster**
Best practices for Non-extraction approach to "Borderline" orthodontic cases
With the kind sponsorship of IOANNIS TSAPRAZIS SA-RMO

# CONGRESS

## HERA ROOM

## DOCTORS AND STAFF PROGRAMM

**Session 1** Chairpersons: Efstathiou E. - Spyropoulos N.

09.00 - 09.45 **Mr. Paul Gange Jr.**
Reducing bond failures on all surfaces - Part 1

09.45 - 10.15 **Assoc. Prof. William Papaioannou**
Effective oral hygiene for the orthodontic patient

10.15 - 10.45 **Mr. Panos Perros**
Digital treatments transforming lives. Facts, insights and more...

10.45 - 11.15 **Prof. Ioannis Tzoutzas**
Safety and effective disinfection in the Orthodontic clinic

11.15 - 11.45 Exhibition visit - Coffee break

**Session 2** Chairpersons: Rontogianni A. - Raisakis Th.

11.45 - 12.30 **Mr. Paul Gange Jr.**
Reducing Bond Failures On All Surfaces Part 2
With the kind sponsorship of UNIDENT - K. Tzivelekas

## DOCTORS AND STAFF PROGRAMM

12.30 - 13.00 **Prof. Stella Chaushu**
Impacted teeth - essential yet overlooked facts in diagnosis and treatment planning

13.15 - 14.30 MOIP Meeting working lunch

**Session 3** Chairpersons: Koutsoumpou D. - Nakou D.

14.30 - 15.00 **Asst. Prof. Eyas Abuhijleh**
Soft Tissue Profile Values in Palestinian Adults

15.00 - 17.30 **Oral Presentations**

15.00 - 15.10 **Panayi Nearchos**, Floros Yiannis
Design it yourself orthodontics

15.10 - 15.20 **Floros Yiannis**, Panayi Nearchos
Print it yourself orthodontics

15.20 - 15.30 **Hasan Amna**, Jayapalan Greeshma, Elzohiery Raghda, Vaid Nikhilesh, Ferguson Donald
Efficacy of premolar extraction cases trested with Invisalign: A petrospective clinical cohort study

15.30 - 15.40 **Exarchou Fotis**
Lingual orthodontics in an aligner world: «Turbo boost» or «Ghost driving»?

15.40 - 15.50 Michelaki E. Iris, **Douma Aikaterini**, Angelopoulos Gerassimos, Tsolakis Apostolos
COVID-19 in a practicing Orthodontists in Greece

15.50 - 16.00 **Elkalza Ahmed**
Can we really accelerate orthodontic tooth movement?

# CONGRESS

16.00 - 16.10 Damanakis Georgios, **Christopoulou Isidora**, Tsolakis Apostolos I.
The impact of diabetes mellitus on orthodontic tooth movement

16.10 - 16.20 **Elkordy Sherif**, Aly Mahmoud Orabi Noha, Palomo Juan Martin, Mostafa Yehya
Three - dimentional airway and skeletal changes with skeletally anchored fixed functional appliances: Data fron 2 randomizedcontrolled trials

16.20 - 16.30 Ozbilen Elvan-Onem, **Papaefthymiou Petros**, Yilmaz Hanife Nuray, Künükkeleş Nazan
Does surgically assisted maxillary protraction with skeletal anchorange and class III elastics effect the pharyngeal airway?

16.30 - 16.40 **Siotou Kalliopi**, Christopoulou Isidora, Georgaki Maria, Tsolakis Apostolos I.
Craniofacial characteristics in a family with osteogenesis imperfecta

16.40 - 16.50 **Scerra Melania-Selene**, Bencivenga Michele-Stanislao, Carfora Marco, Grassia Vincenzo, Perillo Letizia
Maxillary expansion in patients with unilateral cleft lip and palate: Digital dental casts analysis

16.50 - 17.00 **Chiarenza Maria** Chiara, Schiavone Maria-Grazia, Carrino Rossella, Franchi Lorenzo, Perillo Letizia
Early treatments of dentoskeletal class III malocclusion: Modified sec III versus RME/FM

17.00 - 17.10 **Evangelidis Vasileios**, Papadimitriou Aikaterini, Papadopoulos Moschos A.
Dilemmas and treatment options of borderline cases in orthodontics

17.10 - 17.20 **Nucci Ludovica**, Dekel Eyal, Flores-Mir Carlos, Perillo Letizia, Chaushu Stella
Impaction of maxillary canines and its effect on the position of adjacent teeth and canine development: A cone - beam computed tomography study

17.20 - 17.30 **Zarkadi Athanasia-Eirini**, Balli Despoina, Kolokitha Olga-Elpis
Impacted maxillary canine and associated dental anomalies. A retrospective study

20.30 - 22.00 **President´s Reception**

*Sunday, September 16th*

## CONGRESS

### ATHINA ROOM

- Chaushu Stella
- Drescher Dieter
- Kanavakis George
- Keles Ahmet
- Laspos Chris
- Michelogiannakis Dimitrios
- Raickovic David

### HERA ROOM

- Monteiro Pedro Costa

## POST – CONGRESS SEMINAR

### ATHINA ROOM

- Raikovic David

# CONGRESS

**Sunday, September 5th 2021**

## ATHINA ROOM

**Session 4** Chairpersons: Cozzani M. - Vastardi E.

09.00 - 09.30 **Prof. Stella Chaushu**
Missing anterior teeth in young patients face and age oriented ortho-prosthetic treatment

09.30 - 10. 00 **Asst. Prof. Dimitrios Michelogiannakis**
Clinical interdisciplinary management of a patient with cerebral palsy, Class III malocclusion, anterior open bite and gingival overgrowth

10.00 - 10.30 **Asst. Prof. Georgios Kanavakis**
Facial esthetics: A patient-centered approach

10.30 - 11.00 **Prof. Ahmet Keles**
Improving the quality of smile with the interdisciplinary team approach

11.00 - 11.30 Exhibition visit - Coffee break

**Session 5** Chairpersons: Kardara D., Attia Kh. H.

11.30 - 12.00 **Dr. David Raickovic**
PREDICTABILITY, a key word for successful treatment plan in aligner orthodontics?
With the kind sponsorship of INVISALIGN - iTero

12.00 - 12.45 **Prof. Dr. Dieter Drescher**
Change the face! Advances in the treatment of growing Class III patients
With the kind sponsorship of ORTHOSHOP EE- ROYAL ORTHODONTICS

12.45 - 13.15 **Dr. Chris Laspos**
Face or Occlusion?
With the kind sponsorship of INVISALIGN - itero

## HERA ROOM

**Session 4** Chairpersons: Exarchou M. - Papagiannis A.

09.00 - 12.20 **Oral Presentations**

09.00-09.10 **Sella-Tunis Tatiana**, Sarig Rachel, Dan Vardimov Alexander, Hershkovitz Israel, Shpack Nir
Are chin and symphysis morphology facial type dependent? A CT-Based study

09.10-09.20 Sella-Tunis Tatiana, Hershkovitz Israel, Dan Vardimon Alexander, Sarig Rachel, **Shpack Nir**
Variation in chin and mandibular symphysis size and shape in males and females: A CT-Based study

09.20-09.30 **Kassem Islam**
Computer guided neurotoxin injection in hyperactive lip (gummy smile)

09.30-09.40 **El-Bokle Dalia**, Abdel-Ghany Amany-Hassan
A systematic diagnostic diagnostic scheme for excessive gingival display «gummy smile»

10.00 - 10.30 **Dr. Pedro Costa Monteiro**
Treating kids with aligners - My approach with Invisalign Teen & First
With the kind sponsorship of FN ORTHODONTICS

10.30 - 10.40 **Kalia Ajit**
Comparison of biomechanical and surface characteristics of retrieved orthodontic mini screws od three commercially available brands - An in vivo study

10.40 - 10.50 Angelopoulos Gerassimos, **Pratikaki Christina**
Missing upper central incisor: Case presentaions and treatment options

10.50 - 11.00 **Papagiannis Alexandros**, Koletsi Despina, Halazonetis Demetrios J, Sifakakis Iosif
Relapse one week after bracket removal: A 3D superimpositional analysis

11.00 - 11.10 **Sideri Sofia**, Alsulaiman Ahmed, Will Leslie, Motro Melih
Effect of zygosity on vertical, sagittal and airway growth in a twin sample: A longitudinal study

11.10 - 11.20 **Rotolo Rossana**, Nucci Ludovica, Fanuzzi Federica, d'Apuzzo Fabrizia, Perillo Letizia
Temporomandibular disorders and rheumathoid arthritis: Correlation with serology

11.20 - 11.30 **Mizrahi Gilad**, Klein Yehuda, Fleissig Omer, Chaushu Stella
The role of B cells in orthodontic tooth movement

11.30 - 11.40 Michailidis Panagiotis, **Davidovitch Moshe**, Shpack Nir, Iverson Richard
Frictional forces generated by the wedgewise system compared to edgewise appliances under conditions of simulates crowding

11.40 - 11.50 **Klein Yehuda**, Pinto Noy, Fleissig Omer, Barenholz Yechezkel, Chaushu Stella
Immunotherapy based nanotechnology: Cytokine nanoparticles for controlled bone remodeling in orthodontics

11.50 - 12.00 Abramovicz Liat, **Sarne Ofer**, Davidovich Moshe, Sella-Tunis Tanya
Accuracy of artificial intelligence (ceph - X) computer generated landmarks in cephalometrics

12.00 - 12.10 **Papadimitriou Aikaterini**, Dontsos Vasileios, Chatzigianni Athina, Papadopoulos Moschos
Overcoming barriers during ankylosis: Combining orthodontics with corticotomy

12.10 - 12.20 **Shahen Shereef**
Digital indirect bonding in orthodontic

13.15 - 13.45 **Closing Ceremony**

# POST-CONGRESS COURSE

**Sunday, September 5th 2021**

## ATHINA ROOM

Chairpersons: Damanakis G. - Douma K.

14.00 - 15.30 **Dr. David Raickovic**
PREDICTABILITY, a key word for successful treatment plan in aligner orthodontics? Part A

15.30 - 15.45 Coffee break

Chairpersons: Konstantonis D. - Stamou E.

15.45 - 17.15 **Dr. David Raickovic**
PREDICTABILITY, a key word for successful treatment plan in aligner orthodontics? Part B
With the kind sponsorship of INVISALIGN - itero

*Invited Speakers*

**Curriculum Vitae**

**Lecture Summaries**



ΕΤΑΙΡΕΙΑ ΟΡΘΟΔΟΝΤΙΚΗΣ & ΓΝΑΘΟΠΡΟΣΩΠΙΚΗΣ ΜΕΛΕΤΗΣ & ΕΡΕΥΝΑΣ | GREEK ASSOCIATION FOR ORTHODONTIC STUDY & RESEARCH

# PRE CONGRESS

## OLYMPIA III-IV Congress Hall

**Friday, September 3rd**

## **David M. Sarver,** DMD, MS

Dr. Sarver received his DMD from The University of Alabama School of Dentistry and M.S. in Orthodontics from the University of North Carolina in 1979. He is a Diplomate of the American Board of Orthodontics, a member of the Edward H. Angle Society of Orthodontists, a Fellow in both the International and American Colleges of Dentists and is a Fellow in the American Academy of Esthetic Dentistry.

In addition to his private practice, Dr. Sarver's book, «Esthetics in Orthodontics and Orthognathic Surgery» was published in September, 1998. He is also co-author (with Dr. Proffit and White) of the surgical text "Contemporary Treatment of Dentofacial Deformity), and is co-author the 4th, 5th editions and 6th edition of Proffit's classic textbook "Contemporary Orthodontics". He has given more than 400 professional presentations in the United States, Europe, Australia and the Middle and Far East

## Esthetics for a Lifetime –Discover the keys

In dentistry, the goals of treatment are often designed for what are patients wish for, even demand. We all see it-instant satisfaction, immediate outcomes. But when we are anticipating treatment for an adolescent, whether it be strictly orthodontics or including interdisciplinary care, we must often take into account the hard and soft tissue changes that occur over the lifetime of that patient. In other words, we commit ourselves to designing treatment with a longer-term view. In this presentation, Dr. Sarver will cover the principles and newly gathered data on how smiles change with time and how we adapt our treatment approaches in both adolescents and adults. We will cover the essential keys to achieve a comprehensive facial and smile appearance and its importance to the immediate and long-term needs of the patient. In this presentation, Dr. Sarver will cover expanded vision and inclusion of multiple dental and medical professional to be partners in planning and implementation of treatment well beyond a mere transaction.

# CONGRESS

**Saturday, September 4th**

## Prof. Letizzia Perillo

Letizia Perillo is full Professor and Dean of the School of Dentistry, Chairman of the NEBEOP Postgraduate Orthodontic Program, Head of the Orthodontic Division at Multidisciplinary Department of Medical-Surgical and Dental Specialties, University of Campania Luigi Vanvitelli, Naples. She is 2018-2020 Visiting Professor at University of Alexandria, Egypt, 2021 Elected President of the Italian Society of Orthodontics (SIDO), 2022 Elected President of the Mediterranean Orthodontic Integration Project (MOIP), 2018-2020 International Ambassador of the American Association of Orthodontists (AAO) for SIDO, Member of the WFO, AAO, EHASO, EOS, SIDO and CH Tweed Foundation (clinical instructor), and member of the Editorial Board of several orthodontic and dental journals.
Prof Perillo graduated in Medicine and Surgery in 1986 and specialized in Orthodontics in 1989 at the University of Naples Federico II. She completed her orthodontic training with a postgraduate fellowship at the University of Michigan in 1993 and a PhD in Interceptive Orthodontics at the University of Florence in 1997. She is author and co-author of everal scientific publications, 9 books and 10 chapters of books, speaker at national and international courses and congresses. Her main research topics are early treatment, non-extraction treatment, cleft lip and palate, dentofacial orthopedics and genetics.

### «CLP Face Oriented Orthodontics»

Cleft lip and palate (CLP) is the most common craniofacial malformation that an orthodontist will encounter. However, a patient with CLP exhibits a multitude of problems, including functional impairments and aesthetic compromise. So the management of this condition still represents a challenge to the clinicians.
Treatment of CLP patients in mixed dentition will be presented and discussed.

## Prof. Khalem Abdoulazm

Khaled Aboulazm is an assistant professor of Orthodontics and Chairman of Orthodontic Department, Pharos University, Alexandria, Egypt. He is an active board member of the Egyptian Orthodontic Society since 2012, Secretary General of the Arab Orthodontic Society since 2015 and AAO Ambassador 2016-2020 representing Middle East. He is also a member in the WFO, AAO, Arab orthodontic society. Khaled is the coordinator for the main national and international orthodontic events in Egypt and he has been well recognized in Africa and Middle East region for his continuous efforts to promote orthodontic research and disseminate scientific information. He is an active international speaker, actively participating in many scientific congresses and courses worldwide and also the author of many scientific papers and reviewer at Journal of Orthodontic Science. He has been appreciated by the WFO for actively participating in the WFO meetings for the last 5 years and for the organization of the AOS day in the "World village" during the 8th IOC,

London 2015 in conjunction with British orthodontic society. Prof. Khaled had graduated from Faculty of Dentistry, Alexandria University, Egypt in 1999 and specialized in Orthodontics in Alexandria University earning the masters degree in 2004 and the PhD in 2009. His main research topics are: Management of difficult impactions and transpositions cases, Management of Class III cases and face driven orthodontics.

## «A face-driven biomechanical way out for the management of impacted and transposed teeth»

It is the duty of every orthodontist to provide effective and efficient treatment to all patients in terms of facial esthetics and occlusal function. To realize these goals, simple mechanics can be used to correct the pathway of Impacted and Transposed teeth. Maxillary canines play an important role in creating good facial and smile esthetics, since they are positioned at the corners of the dental arch, forming the canine eminence. Besides, they support the dentition, contributing to disarticulation during lateral movements in certain persons. Canines are the second most frequently displaced and impacted teeth in the dentition, showing a prevalence of 1 to 4%. Around 85% of these misplacements are palatal, and they can occur even in patients with adequate arch length. The simple mechanics to manage these problems will be discussed.
"Out of the box" thinking became the norm to treat certain situations that were not easily correctable previously.
This presentation will highlight the use of simplified but efficient biomechanics to solve these problems.

## Prof. Christos Katsaros

Christos Katsaros is Professor and Chair at the Department of Orthodontics and Dentofacial Orthopedics, University of Bern, Switzerland since 2008. He obtained his dental degree from the University of Thessaloniki, Greece, and received his 4-year orthodontic postgraduate training at the University of Saarland, Germany, where he also completed his doctoral thesis and his "Habilitation". Professor Katsaros worked also as a researcher at the Göteborg University, Sweden, where he completed a Ph.D.. From 2000 to 2002 he served as an Associate Professor and from 2002 to 2008 as a Professor of Orthodontics at the Department of Orthodontics and Oral Biology, Radboud University Nijmegen Medical Centre, Nijmegen, The Netherlands. His current research interests include the elucidation of the molecular mechanisms that control face development and wound healing in CLP as well as the prevention and therapy of gingival recession in orthodontic patients. He serves as Associate Editor for the AJO-DO, as Section Editor Dentistry for the Cleft Palate-Craniofacial Journal and he is editorial board member or reviewer for several international scientific journals. He is Council member and Past President of the European Orthodontic Society (EOS) and an Active Member of the Angle Society of Europe.

## «With the face in mind does orthodontic tooth movement induce the development of gingival recession?»

Active orthodontic tooth movement can induce gingival recession when teeth are moved outside the alveolar envelope. However, the available

scientific evidence does not give a definitive answer to the question whether orthodontic treatment is a major risk factor for the development of gingival recession in the long-term. The same is true regarding the role of individual patient-related or treatment-related contributing factors. Four main questions will be addressed: Is orthodontic tooth movement a major risk for gingival recession? Do orthodontically treated patients suffer in the long run more from gingival recession compared to untreated individuals? Does prolonged fixed retention influence the development of gingival recession? How can the periodontist assist in the prevention or treatment of gingival recession? The understanding of the association between orthodontic tooth movement and development of gingival recession is important because of the high number of children, teenagers and adults who are treated orthodontically.

## Prof. Effie Basdra

Effie K. Basdra graduated from the Dental School of Aristotle University of Thessaloniki, completed her postgraduate studies in Orthodontics at Columbia University in New York., USA and obtained her PhD and Habilitation in biomechanics at the Medical School of the University of Heidelberg, Germany. She served as Editor-in-Chief in WJO and is member of Editorial Boards of many international journals in her field. She has published extensively in the field of biomechanics. She is professor of Biochemistry-Biomechanics at the Medical School of the National and Kapodistrian University of Athens and leads the Cellular and Molecular Biomechanics Unit. She served as President of the State Scholarship Foundation and special advisor at Eurobank for fellowships of excellence and innovation. She is member of the Advisory Board of the think tank DiaNeosis, the Advisory Board of the Greek Diaspora Fellowship Program of the Stavros Niarchos Foundation and President of GAOSR.

### «How we move teeth after all? An up-to-date biological insight»

In the era of molecular medicine, artificial inteligence (AI), targeted pharmaceutical approaches and robotic biofabrication of architected biomaterials that heal, the biological underpinning of orthodontic tooth movement, TMJ and fossa remodeling, cranial suture expansion, are gradually being unveiled. To our knowledge mechanical loading and unloading act as the triggering factor that through a series of cellular and molecular events engaging mechanosensitive molecules i.e., polycystins, control bone remodeling. Mechanotransduction seems to be of pivotal importance in all biological systems as it has been demonstrated lately to be also a key regulator in cancer biology and the tumor metastasis process.

## Prof. Nikhilesh Vaid

- President of the World Federation of Orthodontists.
- Past President of the Asian Pacific Orthodontic Society & Indian Orthodontic Society.
- EIC Emeritus, APOS Trends in Orthodontics.
- Guest Editor- Seminars in Orthodontics:2016-Dec,2018-March & Dec,2021-June.
- Authored 140 plus papers, text book chapters and lectured in more than 50 countries globally.

- Orthodontic enthusiast and student at heart
- Professor & Vice Dean, European University College,DHCC,Dubai,UAE.
- Director at «Only Orthodontics», Mumbai,India.

## «Artificial Intelligence driven Orthodontics : A quest for utopia?»

AI applications in Orthodontics are relatively young but growing at a rapid pace.
This presentation aims to- 1) Explain conceptually how AI algorithms work. 2) Classify AI applications and their scope in orthodontics. 3)Assess clinical scope, performance and risks associated with therapeutics. 4)Propose an outline for audit of AI applications in orthodontics.
The lecture will explain how AI is a set of tools for problem-solving that can assist orthodontists with extra powerful and applied tools to provide better standards of care. AI can assist orthodontists to choose the best way to move a tooth or group of teeth, but AI today completely ignores the existence of oral diseases, does not fully integrate facial analysis in its algorithms, and is unable to consider the impact of functional problems in treatments.
The lecture will also dwell upon the risks associated with AI application. As AI enters practice, clinicians need to know how law will assign liability for errors that arise from interaction between algorithms and practitioners. These issues are likely to arise sooner rather than later. Responsibility and the varied scope of these applications will also be deliberated.

## Prof. Josef Ghafari

Prof. Joseph Ghafari earned dental degrees from the Universiti Saint Joseph (Lebanon) and the University of Pennsylvania (U/PA, USA), and orthodontic education at Harvard University/Forsyth Dental Center. He is a former Professor and presently Adjunct Professor of Orthodontics at U/PA. He is Professor and Founding Head of the Division of Orthodontics and Dentofacial Orthopedics, American University of Beirut. A Diplomate of the American Board of Orthodontics, and past or present President of national and international associations, he has a rich portfolio of research, publications, and invited lectures worldwide. He has received awards and recognitions from various professional organizations and academic institutions.

## «Facial esthetics in the eyes of the orthodontist: therapeutic potential and limitations»

Studies indicate that averageness in facial proportions translates into attractiveness. While this tenet was challenged in the definition of beauty going beyond averageness, the average remains a guide for treatment by practitioners concerned with facial esthetics. Accordingly, treatment to the normal Class I occlusion prevails but does not necessarily correspond to favorable or enhanced facial esthetics. Discrepancies among hard structures (bone and teeth) in relation to soft tissue variation in thickness and proportion indicate that treatment short of Class I occlusion may be appropriate as the severity of skeletal discrepancy increases. This concept will be illustrated with treatment reports and research findings.

## Dr. Chad Foster

Chad Foster is a board-certified orthodontist and owner of Butterfly Orthodontics in Phoenix, Arizona. A graduate of Chapman University, he earned his Doctor of Dental Surgery and a master's degree in craniofacial biology and completed his orthodontic residency at the University of Southern California where he was awarded the Harry L. Daugherty Award as top clinician in his class. Dr. Foster loves orthodontics and supporting his orthodontic colleagues.
He is an avid reader, prolific writer, and lectures internationally, most often on the topic of orthodontic esthetics. He is also honored to serve as the Editorial Director of Orthotown Magazine.

### «Everyday Esthetics- 45 clinical tips in 45 minutes»

This will be a content-packed discussion on a variety of clinical topics in the field of esthetics. The fast paced lecture will cover 45 case tips from diagnostics, efficient treatment mechanics, all theway through retention.

### «Best practices for Non-extraction approach to «Borderline» orthodontic cases»

«Borderline» orthodontic cases are defined as those which could likely be treated either with or without traditional bicuspid extractions. They most often present with moderate to severe crowding and or significant dental protrusion. These in the author's opinion, are often the most interesting types of orthodontic cases. This lecture will present a large number of borderline cases treated with a non extraction approach that is detailed with specific recommended protocols and mechanical tips.
With the kind sponsorship of IOANNIS TSAPRAZIS SA - RMO

## Dr. Raffaele Spena

Dr Raffaele Spena received his Certificate in Orthodontics at the University of Pennsylvania, Philadelphia in 1988. In 2003, he received the degree of «Specialty in Orthodontics» at the University of Ferrara. He has been speaker at both Italian (SIDO, SITEBI, ANDI, Italian Accademy of Orthodontics) and international meetings. In July 1998, he published an atlas about «Il trattamento senza estrazioni» (Nonextraction technique) that has been published in English by Fenske Media Corporation in 2002. In 2000, he published with the drs. R.L.Vanarsdall and N.M. Cetlin a chapter «Nonextraction Treatment» in the textbook «Orthodontics – Current principles and techniques» by T.M.Graber e R.M.Vanarsdall. An updated chapter, written with the same co-authors, has been included in the new editions (2005 and 2011) of the same book edited by T.M.Graber, R.M.Vanarsdall e K.W.L.Vig. Dr. Spena has been Adjunct Clinical Professor at the Orthodontic Department of the Dental School of the University of Pennsylvania from 1988 to 2000 as well as at the University of Parma from 1996 to 2000. At the moment, he is Adjunct Clinical Professor at the University of Ferrara. Dr. Spena has been President of the Italian Academy of Orthodontics for the year 2010 and has been Scientific Secretary of the same society in the years 2008-2009. He is an active member of the Angle Society of Europe since 2005. In 2001, he has received the Certificate of Excellence in Orthodontics in Italy and, in 2008, the E.B.O. (European Board of Orthodontics). He practices orthodontics in Napoli.
With the kind sponsorship of M. VITSAROPOULOS

## «Complex Cases - Solutions utilizing revisited diagnostic and biomechanical protocols»

This paper has the objective to present diagnosis, management and solutions of orthodontic problems of diverse frequency and complexity. A personal perspective on skeletal anchorage, stimulation of patient's response and effective appliances will be shown and how they may be utilized to help manage cases in a direction different from what is commonly advised in the literature

## Paul Gange Jr.

Paul Gange Jr. has been involved in Orthodontics since 2008.He has become a leader in resolving difficult technical bonding issues through countless hours training chairside staff. His passion for research and development has influenced many new Reliance products and aided numerous research projects. Paul is a published author, lectures domestically and internationally at numerous universities, study clubs, constituent meetings as well as the AAO. His greatest fulfillment comes from hands-on training for doctors and staff in private offices

## «Reducing Bond Failures on All Surfaces»

Attendees will experience a comprehensive review of the most critical stage of orthodontic treatment - the bonding appointment! Topics discussed will be artificial substrate preparation, bond failure reduction, failure diagnosis, various types of enamel preparation, decalcification prevetion, and appliance delivery. Additionally, specific time will be assgined to demonstrate how clinicians can evolve with the digital wave without losing sight of the ever-changing critical bonding process.

With the kind sponsorship of UNIDENT - K. Tzivelekas

## Asst. Prof. William Papaioannou

William Papaioannou graduated from the Dental School of the Aristotle University of Thessaloniki (Greece) in 1992. Continuing in the postgraduate program of the Catholic University of Leuven (Belgium) he attained the degrees: Master in Dental Sciences, Doctor in Medical Sciences (Ph.D.) and the specialization in periodontology.

He is currently an associate professor of Preventive and Community Dentistry in the School of Dentistry, National and Kapodistrian University of Athens. His research interests focus on the etiology and prevention of oral diseases, with special attention to oral microbiology. He maintains a private practice limited to Periodontology and Dental Implants. He has authored more than 70 papers in peer reviewed journals (such as Journal of Periodontology, Clinical Oral Implants Research, Anaerobes etc.) and has lectured in Greece and internationally. He is the Secretary General of the Hellenic Society of Periodontology and member of the Board of the Continental European Division of the International Association for Dental Research (CED-IADR).

## «Effective oral hygiene for the orthodontic patient»

Orthodontic therapy, due to the insertion of either fixed or removable

appliances, causes significant changes in the oral microbiome. Without proper guidance and continual motivation it is relatively easy for patients to inadequately clean around the orthodontic appliances and thus fail to sufficiently control the bacterial load around teeth and in the oral cavity. As a result, demineralization of the tooth surfaces and caries development and/or gingival inflammation may ensue. Oral hygiene instruction and monitoring of its proper implementation is of paramount importance for the orthodontic patient and should be initiated even before the start of treatment. Indeed, the patients undergoing orthodontic therapy should invest extra time and effort in performing oral hygiene, since they in essence comprise a distinct group of high-risk patients for dental disease. Therefore, time must be spent in the initial consultations to fully explain the various aspects of oral health and disease and the methods of oral hygiene that must be used. Throughout the various stages of therapy the level of oral hygiene must be evaluated and proper supplemental information given to the patient. Current research is focused on reducing the impact of modifying factors (i.e. cementing material or bracket type) on the adhesion and/or retention of bacteria or the use of clear aligners to facilitate the daily cleaning of teeth. who are treated orthodontically.

## Panos Perros

Panos Perros is a qualified entrepreneur with more than 20 years of orthodontic sales, technical, clinical, consulting and marketing experience. Over the last 11 years he has been leading the local customer support, clinical support and sales teams towards developing Invisalign and iTero expansion in Greece Cyprus, Bulgaria and Malta.

Panos enjoys working closely with dental professionals, doctors and their teams, developing strategic solutions to drive their businesses forward, especially in highly challenging economic and competitive environment.

Since 2012 has lectured to over 150 educational seminars in the mentioned 4 countries, having delivered countless hours of business coaching to the dental industry. Panos has a unique sales process, powerful systems and methods, which includes sharing proven strategies and coaching delegates in an empowering way, allowing them to develop new skills. Dentists, orthodontists, treatment coordinators, specialists and other team members will be able to perform better and more patients will say YES to proposed treatment plans.

Happy father and husband tries, without success, to have more time with his family...

### «Practice management considering the era of digital treatments. Facts, insights and more...»

Prepare your practice to effectively respond to patients needs and expectations. Embrace technologically advanced ways from patient consultation, to treatment delivery and monitoring processes. Seek clinical excellence and get the maximum of patient experience. How aligners and scanner are integrated into orthodontic practices and change the norm in Orthodontia? Concrete management solutions based on facts , data, statistics and sharing 10 years of experience from Greek and other European markets. Great challenges ahead for doctors and staff...be ready.

## Prof. Ioannis Tzoutzas



Since 2015 Dr. Tzoutzas is Professor in the University of Athens, School of Dentistry. Graduated from Athens University, School of Dentistry. He was partner in research and education Issues in the Univ. of Southern California, USA where he served as Assistant Professor.
Dr Tzoutzas is currently Vice-President of the Athens Dental Association and member of the governing board of the Hellenic Dental Association. He is chairing the Infection control and Waste management Working Group of the Council of European Dentists (CED). President of the Scientific and Continuous Education Committee of the Athens Dental Association, member of various committees of the University of Athens, the Ministry of Health and the Council of European Dentists. Scientific Editor of the Hellenic Stomatological Review, the official scientific publication of the Hellenic Dental Association published trimonthly and thrice President of the Faculty members' Association of the University of Athens, School of Dentistry.

### «Safety and effective disinfection in the Orthodontic clinic»

The specialty of orthodontics has the advantage, among other things, of not using materials, tools and techniques that create a serious substrate for cross-infections that are common in interventional and reconstructive dentistry. However, oral flora remains present and modern implantation techniques have significantly altered infection control protocols.
Rotary tools are the most vulnerable to corrosion processes and therefore it is advisable to avoid wet heat techniques for sterilization. The use of modern safe, effective and non-aggressive cleaners, lubricants and disinfectants is the solution of choice for the proper functioning of the orthodontic practice, provided that they are used correctly and precisely for the intended and prescribed uses.
Alcoholic compounds, together with quaternary ammonium compounds, together with Enzymes are the materials of choice for the disinfection and cleaning of orthodontic tools, provided that their application times and indications of use are followed.

## Prof. Stella Chaushu

Prof. Dr. Chaushu is Professor and Chairperson of Department of Orthodontics in Jerusalem. She is coordinator of three different fields in the department: Adult Orthodontics, Impacted Teeth and Special Needs children and holds a PhD degree in Immunology. The results of her research activities have been published in over 100 articles in peer-reviewed journals and in 13 chapters in books. Dr. Chaushu is member of the Editorial Review Board of the AJODO and past Associated Editor of Progress in Orthodontics and reviews manuscripts for many international journals. Invited speaker at many international congresses on aspects related to impacted teeth and the orthodontic-periodontic interface.

### «Impacted teeth - essential yet overlooked facts in diagnosis and treatment planning»

One of the main factors which complicate treatment of impacted teeth is that the tooth is not visible, therefore positional diagnosis and planning is

often difficult. Existing clinical clues are often overlooked even by experts. Recognition of these clues before treatment is essential for early diagnosis, preventive measures and correct planning of the ortho-surgical resolution, while recognition of these clues during treatment is a key in avoiding failures. This presentation provides the clinician tools for a better 3D clinical diagnosis and planning of treatment timing and strategy, by presenting clinical cases and new research data from a multicentre study.

## «Missing anterior teeth in young patients - face and age oriented ortho-prosthetic treatment»

A missing front tooth increases the orthodontic treatment complexity and rises many dilemmas for both orthodontist and prosthodontist. The main treatment principle is to begin with the end in mind, which means starting with a full understanding of the desired result and then working backwards to make it possible. Digital multidisciplinary planning and periodical team evaluation are critical. It is essential that each practitioner is periodically updated on the latest advances in the other profession. The present lecture follows up several young patients who lost their front teeth, discusses the difficulties and presents up-to-date solutions based on face and age-oriented ortho-prosthetic approaches.

## Asst. Prof. Eyas Abuhijleh

Dr. Abuhijleh is an Assistant Professor and a Specialist Orthodontist working in Ajman University from February 2017 until now. He worked in Tawam hospital Dental Center in affiliation with Johns Hopkins medicine from July 2007 to Decemeber 2013, then in Al Ain Dental center AHS-Seha from December 2013 to February 2017. He worked in Ankara university and Ajman university of science and technology from 1999-2007. He received his BDS degree of Dentistry from the Jordan University of Science and Technology and his orthodontic clinical training and clinical Ph D from Ankara University. He has co-authored numerous articles in Angle Orthodontist, European orthodontic journal, oral science journal and Turkish orthodontic journal. He has lectured extensively in national and international conferences as a key note invited speaker.

## «Soft Tissue Profile Values in Palestinian Adults»

**Objective**: To obtain standards for the soft tissue facial profile for male and female Palestinian adults using Holdaway and Legan-Burstone cephalometric analyses.

**Materials & Methods**: 77 lateral cephalometric radiographs for non-growing Palestinian adults (46 males and 31 females) with normal occlusion were traced and measured.

**Results**: When compared to Holdaway norms, Palestinian adults have similar values of except for the skeletal profile convexity, H angle, and basic upper lip thickness, which were larger in Palestinians. When compared with Legan-Burstone norms (facial form analysis), Palestinians showed similar values except for decreased mandibular prognathism and increased lower face-throat angle. Comparison between men and women showed that basic upper lip thickness, upper lip thickness, and inferior sulcus to H-line were significantly larger in Palestinian men when compared to Palestinian women.

**Conclusion**: The results of this study indicates that the soft tissue facial

profiles for Palestinians and the values of Holdaway and Legan-Burstone are different. Such differences should be taken in to consideration when formulating a treatment plan for Palestinian patients seeking orthodontic treatment and/or orthognathic surgery.

## Asst. Prof. Dimitrios Michelogiannakis

Dr. Dimitrios Michelogiannakis is an Assistant Professor of Clinical Dentistry at the Division of Orthodontics and Dentofacial Orthopedics, Eastman Institute for Oral Health (EIOH), University of Rochester, NY; and maintains a faculty practice limited to Orthodontics. He received his dental degree (DDS) from the National and Kapodistrian University of Athens, School of Dentistry, Athens, Greece in 2012; and completed a 3-year specialty training program in Orthodontics and Master of Science degree (MS) at the EIOH in 2017.

Dr. Michelogiannakis is a diplomate of the American Board of Orthodontics, and a member of several professional organizations such as the American Association of Orthodontists (AAO), the American Dental Association (ADA), and the American Dental Education Association (ADEA). He has received further certifications in the field of Orthodontics such as from the Charles H. Tweed International Foundation and the Wilckodontics Certification in Accelerated Osteogenic Orthodontics.

His main research theme has been to evaluate the influence of various factors such as nicotine, obesity, medications, developmental and dental conditions, type of malocclusion, treatment mechanics and patient expectations on orthodontic tooth movement and related parameters. He has contributed several publications in peer-reviewed journals including scientific articles and a book chapter. Dr. Michelogiannakis is currently participating in original research studies regarding the influence of non-extraction clear aligner therapy on alveolar bone and airway dimensions in adult patients.

### «Clinical interdisciplinary management of a patient with cerebral palsy, Class III malocclusion, anterior open bite and gingival overgrowth»

Cerebral palsy (CP) is a developmental disorder that leads to impaired muscle function. Patients with CP often suffer from poor orofacial muscle control which may negatively influence occlusal development and craniofacial growth, and lead to dentofacial disharmony and functional limitations. However, medical and behavioral challenges in patients with CP often prevent practitioners from offering the necessary dental care. The clinical interdisciplinary management of a 20-year-old male patient with CP, anterior open bite, Class III malocclusion, and gingival overgrowth will be presented including a combined orthodontic, periodontal and orthognathic surgery treatment approach.

## Asst. Prof. Georgios Kanavakis

Georgios Kanavakis is a Senior Lecturer in the Department of Pediatric Oral Health and Orthodontics at the University of Basel in Switzerland, and a Visiting Assistant Professor in the Department of Orthodontics at Tufts University, School of Dental Medicine in Boston, MA. He is a Diplomate of the American Board of Orthodontists.

Dr. Kanavakis received his dental degree at the Aristotle University of Thessaloniki, School of Dentistry. He holds a postgraduate certificate in Temporomandibular Disorders and Orofacial Pain, a Master of Science, and a postgraduate certificate in Orthodontics and Dentofacial Orthopedics from Tufts University, School of Dental Medicine.

Dr. Kanavakis has published more than 30 articles in peer-reviewed orthodontic journals, has co-authored three orthodontic book chapters and is a reviewer for several orthodontic publications. His main research interests focus on Factors affecting the Perception of Facial Appearance, Three-Dimensional Facial Analysis, 3D Imaging, as well as the use of skeletal anchorage in orthodontic clinical practice.

### «Facial esthetics: A patient-centered approach»

Facial and smile esthetics are the main reasons for patients of all ages to seek orthodontic care. The new paradigm in orthodontic treatment planning focuses on facial and smile appearance, as well as overall improvement in quality of life. However, facial esthetics and soft tissue morphology are assessed with traditional norms that do not take into consideration patients' perceptions.

This presentation will focus on factors that influence self-perception of facial and smile appearance. How do objectives features influence our opinion and to what extent do personality and self-esteem affect our perception? Which facial features tend to have the most significant impact on self-perceived facial and smile attractiveness? Within this context, the overall role of the orthodontist in modern times will be revisited and the social impact of our profession will be discussed.

Learning objectives:

1. Attendees of this lecture will be able to recognize the effect of physical and psychological factors on self-perception of facial and smile appearance.
2. To evaluate differences between genders in self-perception of facial ansd smile attractiveness.
3. To revisit and redefine the impact of orthodontics in patients' lives and modern society.

## Prof. Ahmet Keles

After graduating from Istanbul University Faculty of Dentistry in 1989, Ahmet Keles started the orthodontic residency program at Harvard University in the U.S. with the scholarship. In 1994, he completed his doctorate degree, and his thesis study received The Thomas Graber Award of Special Merit given by American Association of Orthodontics. After completing his doctorate, he taught orthodontics at Marmara University. After acquisition his Associate Professorship in 2002, he served as Clinical Director of Orthodontics at University of Connecticut until 2005. Afterwards,

he started teaching at Harvard University as a part time faculty. Currently, he divides his time between Istanbul, seeing patients in his private practice and in Boston teaching postgraduate students at Harvard University. He received his full Professorship from Istanbul Aydin University in 2018. Ahmet Keles has many patents bearing his name. His inventions, Keles Keyless Expander, Keles Slider and Keles Face Mask are produced and widely used in United States. He travels widely to give courses and seminars in orthodontics. He has authored more than 50 scientific publications and many orthodontic textbook chapters. He was the abstract and reviews editor of the World Journal of Orthodontics. He is currently the Vice President of Harvard Society of Advancement of Orthodontics. He is married and has 2 children.

## «Improving the quality of smile with the interdisciplinary team approach»

Clear Aligners and lingual braces are getting more and more popular nowadays. Especially because of their esthetic appearance and being invisible adult orthodontic treatment has increased its popularity. Many patients, especially adults often have dental needs that may require restorative care, treatment or management of the periodontium and enhancing esthetics in conjunction with braces. In such situations achieving an optimal esthetic and functional result requires the expertise of more than one clinician. In these cases we elect for collaborative approach that involves the patient's general dentist and other specialists to develop and sequence a unified treatment plan to achieve the best possible result. This interdisciplinary approach to treatment is extremely effective for such complex cases where one specialist alone cannot deal with all aspects of the problem. As a patient you benefit from the combined expertise of many clinicians/ specialists working closely together to develop a blue print to guide your care. This collaborative approach ensures that as a patient you receive the best possible care at every step of the treatment process. The team approach allows for more efficiency with a better, more stable and lasting treatment outcome.

## Dr. David Raickovic

Orthodontic specialist, international speaker

- MSc Module Director at City of London Dental School
- Invisalign Diamond Provider and Clinical Speaker
- World Top 1% Invisalign Provider 2019
- GC Orthodontics Key Opinion Leader and Clinical Speaker

Experience:

| | |
|---|---|
| 2020 - present | Associate Orthodontic Specialist at "Happy Kids Dental", "American Smile", London, UK |
| 2020 - present | Associate Orthodontic Specialist at "The Orthodontic Specialist", Amersham, UK |
| 2016 - 2020 | Associate Orthodontic Specialist at "Poliklinika Identalia", Zagreb, Croatia |
| 2012 - 2013 | visiting student at Dr. Yon H. Lai Orthodontic Clinic, New York, USA |
| 2007 - present | Owner at "DR. DAVID digitalna ortodoncija", Split, Croatia |

Education:

2016 Orthodontic Residency at KBC Zagreb, Croatia
2013 International Orthodontic Residency, New York University, New York, USA
2007 DMD School of Dental Medicine, University of Zagreb, Croatia
Continuing Education:
2019. Kenji Ojima Aligner Master Course, Tokyo, Japan
2019. Master COIP update, Madrid, Spain
2019. GC Orthodontics speakers meeting, Leuven, Belgium
2018 Master COIP update, Madrid, Spain
2018. Invisalign and TADs, Porto, Portugal
2018. GC Orthodontics, GET Congress, Budapest, Hungary
2018. K&K Diamond Master Class, Bioaligner Institute, Madrid, Spain
2018. 2nd European Aligner Symposium, Venice, Italy
2017. Master COIP update, Madrid, Spain
2017. Advanced Master COIP, Madrid, Spain
2017. 1st European Aligner Symposium, Vienna, Austria
2017. Master COIP, Madrid, Spain
2016. EUMAA Invisalign Master Class, Bratislava, Slovakia
2013. The Greater New York Dental Meeting, New York, USA
2012. American Association of Orthodontics, Philadelphia, USA
2012. The Greater New York Dental Meeting, New York, USA
Associations member:
New York University Alumni (NYU ALUMNI)
Consortium for Translational Orthodontic Research (CTOR)
American Association of Orthodontists (AAO)
American Dental Association (ADA)
European Aligner Society (EAS)
Hrvatsko Društvo Ortodonata (HDO-HLZ)

## «PREDICTABILITY, a key word for successful treatment plan in aligner orthodontics»

In every step of your treatment plan assembly you should ask yourself "Is this movement, or sequence of movements, predictable"? Why? Because your input in your treatment plan simulation will always be achievable virtually but will you get it in real life? That's the question which will make a difference between successful outcome or and a failure.
In this presentation I will guide you through treatment plan assembly emphasizing predictability in every step of the way which will give you a successful outcome in aligner orthodontic treatment. When it comes to cases like open bites, wether they are dental, skeletal or both at the same time, I am sure that we all will categorize them as challenging and difficult. After treating countless open bite cases with fixed appliances (brackets and wires) and also with Invisalign aligners I can easily state that my "weapon of choice" for open bite malocclusion is absolutely Invisalign aligners. The predictability, efficiency, practicality and capability of Invisalign aligners in treating open bites is second to none!
Join me in my lecture where I will show you cases, mechanics, attachment, and protocols for treating various open bite and other challenging malocclusions with Invisalign aligners
With the kind sponsorship of INVISALIGN - iTero

## Prof. Dr. Dieter Drescher

Study of dentistry from 1977 to 1982 at the University of Bonn. Doctorate thesis in 1984. Postgraduate education in Orthodontics from 1984 to 1988. Ph.D. in 1991. Head of the Department of Orthodontics at the University of Bonn from 1993 to 1997. Since 1997 professor and head of the Department of Orthodontics at the Heinrich-Heine-University of Dósseldorf. From 2002 to 2019 Prof. Drescher served as Executive Director of the Center of Dentistry at the University of Dósseldorf. Prof. Drescher published more than 130 articles and lectured all over the world. His main interests focus on skeletal anchorage, dentofacial orthopedics, biomechanics, and smart materials.

### «Change the face! Advances in the treatment of growing Class III patients»

Recent systematic reviews have shown that maxillary protraction in young patients with a retrognathic maxilla is much more effective when using skeletal anchorage. A minimally invasive approach to establish skeletal anchorage in the upper jaw is to utilize mini-implants inserted in the anterior palate. This insertion site comprises a very good bone quality and quantity. Several clinical studies documented a superior reliability of mini-implants inserted in the anterior palate with success rates ranging between 96% and 98%.
In order to perform simultaneous rapid maxillary expansion and protraction the Hybrid-Hyrax is utilized either in conjunction with a face mask or a Mentoplate. The effectiveness of maxillary protraction can be even enhanced following the Alt-RAMEC protocol.
Utilizing computerized design and metal printing technologies in conjunction with insertion guides the Hybrid-Hyrax can be inserted in just one appointment. The newly developed clinical workflow proved to be very efficient and reliable.
Based on many clinical examples the indications, clinical procedures and outcomes of maxillary protraction in growing Class III patients are discussed.
With the kind sponsorship of ORTHOSHOP EE- ROYAL ORTHODONTICS

## Dr. Chris Laspos DDS, MDS

Dr. Chris Laspos is an orthodontist specialist in individuals with craniofacial malformations.
He received his DDS (1995) from the Dental School of the University of Athens. He was a research fellow in the TMJ and Orthodontic Department at the University of Rochester, Eastman Dental Center of Rochester, New York. He specialised in orthodontics (Master of Dental Science)(1996-1999) in the College of Dentistry, University of Tennessee. He specialised in individuals with craniofacial malformations (Craniofacial Fellowship (1999-2000), in the University of Texas, Southwestern Medical Center.
Since the year 2000, he practices in his private orthodontic center in Limassol, Cyprus. He is the founder and director of the Cyprus Center for Clefts and Facial Deformities, "Medicleft" and of the "Chrysallida Foundation", the Cyprus association of individuals with clefts and other craniofacial anomalies. He is the director of the Synergy Dental Academy that provides continuing education courses for dental professionals.
He is an Active member of the Angle Society of Europe, and Certified of the European Board of Orthodontics. He is currently an examiner of the EBO. He published in European and American scientific journals and he lectures

internationally on craniofacial malformations, orthognathic surgery, multidisciplinary approach, and new technologies in orthodontics.
He is the president elected of the European Orthodontic Society (2021).

## «Face or Occlusion?»

Orthodontists around the globe are trained to treat every individual to an ideal Class I occlusion. The use of new biomaterials combined with advanced technology offer a considerable armamentarium to facilitate almost every case in the desired occlusion.
Individuals with skeletal discrepancies, however, constitute cases requiring good judgment, critical evaluation, as well as an individualized treatment plan from both the orthodontist and the oral and maxillofacial surgeon in order to achieve good results.
We will present several cases, which in spite of the fact that they were orthodontically treated in a nice class I occlusion, the face and the skeletal discrepancy were overlooked by the orthodontist. These four patients were referred to our clinic after the completion of the orthodontic treatment complaining about the esthetic outcome.
This presentation illustrates very clearly:
a) The failure of the orthodontist to understand the real major complaint of the patient or
b) The inability of the orthodontist to present the option of surgical correction to the patient, either because of lack of experience or due to inadequate knowledge or personal beliefs regarding surgical orthodontic approaches.
A second treatment was necessary in all four cases. The extra cost and the extra time involved are issues which illustrate the lack of good judgment initially. The new treatment approach that focuses equally on the occlusion and the face will be presented. This presentation emphasizes emphasis on the cooperation between the orthodontist and the oral and maxillofacial surgeon.
With the kind sponsorship of INVISALIGN - itero

## Dr. Pedro Costa Monteiro

DDS by Faculdade de Medicina Dentaria do Porto, Oporto University, Portugal 2002
MSC Orthodontics and Facial Orthopedics by ISCS-Norte, Oporto University, Portugal 2008
Private Practice limited to orthodontics since 2004 at Oporto Portugal - Clinica PCMFG
Invisalign Diamond II Provider, KOL & Speaker since 2018
Dental monitoring KOL & Speaker since 2019
Vice President of Portuguese Aligner Society - SPAD
CEO & Co-Owner of Master Aligner Portugal & of Master Aligner Online Academy.

## «Treating kids with aligners - My approach with Invisalign Teen & First»

Phase I treatment is an exciting area of expansion for clear aligner therapy and will only continue to grow in the next few years.
Since 2018, I have been working with Invisalign First with patients from 6 to 12 years old.
In this conference I will share my experience after finishing more than 80 treatments and talk about my protocols on transversal problems, sagittal problems and vertical problems in young kids and teenagers.
With the kind sponsorship of FN ORTHODONTICS

*Abstract Book*

## Free Topic Oral Presentations

## Posters

Abstract Book

ΕΤΑΙΡΕΙΑ ΟΡΘΟΔΟΝΤΙΚΗΣ & ΓΝΑΘΟΠΡΟΣΩΠΙΚΗΣ ΜΕΛΕΤΗΣ & ΕΡΕΥΝΑΣ | GREEK ASSOCIATION FOR ORTHODONTIC STUDY & RESEARCH

*Gala Dinner will take place at the Roof Garden of Wyndham Grand hotel*

# FREE TOPIC ORAL PRESENTATIONS.

## 1. Design it yourself orthodontics

**Dr. Nearchos Panayi**, Dr. Yiannis Floros
Athens Medical School, National and Kapodistrian University of Athens, private practice Limassol, Cyprus.

**Aim**: To present novel 3D technologies and concepts using a general purpose CAD software for designing orthodontic devices and a new Orthodontic CAD software for designing customized Orthodontic brackets in the orthodontic office.

In the last decade, digital technology has entered everyday orthodontic practice. The use of digital data alters the conventional practice of treating orthodontic problems, resulting in safer diagnosis and selection of the most appropriate treatment plan and appliance. In addition, digitization of the patient's diagnostic data enables the 3D computer aided design (CAD) of customized orthodontic devices. General purpose, not dedicated Orthodontic CAD software, can be used for 3D designing. Moreover, a new Orthodontic CAD software can be used to design customized labial and lingual orthodontic brackets in the Orthodontic office.

The ease of design of the orthodontic appliance, its precision, its customization without the intervention of the classical dental laboratory enables the Orthodontist to control each stage of the appliance's design. The only element that differentiates the design of digital orthodontic appliances is the imagination of every clinical Orthodontist.Many examples of 3D designed devices will be presented together with orthodontic cases using the innovative Orthodontic software for in-house design of customized orthodontic brackets.

## 2. Print it yourself orthodontics

**Dr. Yiannis Floros**, Dr. Nearchos Panayi
Private practice, Athens

**Aim**: To present various 3D printers based on different technology with focus to the printers for Orthodontic use. In addition, present new resins for Orthodontic use, clinical examples of printed orthodontic devices and the novel technology of in-house aligner printing and in-house customized orthodontic brackets printing.

3D Additive Manufacturing (printing), of an Orthodontic appliance is the next important step after designing an Orthodontic appliance. Additive manufacturing (printing) is giving life to our virtually designed appliances. 3D Printing is a big chapter in manufacturing technology consisting of many different manufacturing techniques. There is a big variety of biocompatible materials for 3D printing that can be used to manufacture our appliances. Printing of orthodontic appliances can be performed in special laboratories or in the Orthodontic office. The new concepts of direct aligner printing and customized bracket printing that are performed in the Orthodontic office will be presented. Moreover, printing of metallic Orthodontic devices performed in laboratories will be discussed.

## 3. Efficacy of premolar extraction cases treated with invisalign: a retrospective clinical cohort study

**Amna Hasan**, Greeshma Jayapalan, Raghda Elzohiery, Nikhilesh Vaid, Donald Ferguson
European University College in Dubai/UAE

**Aim**: To evaluate cephalometric changes and differences between predicted and achieved tooth movements (DPATMs) in Invisalign premolar extraction patients.

**Materials & Method**: Records of consecutively treated adult Invisalign patients were evaluated by blinded observers. Cephalometric evaluations were carried out in 25 patients (26 values). DPATMs were computed from digital STL records of 32 patients using the Compare 9.1 software. The DPATMs per tooth group were assessed and compared to ABO clinical significance guidelines.

**Results**: The statistical test employed were Shapiro Wilk test and Paired T- test, treatment changes were evaluated at 95% confidence intervals. On cephalometric evaluations, incisal angulations were retroclined respective to their basal bones in both arches and a clinically insignificant decrease in soft tissue profile was noted. Upper and lower soft tissue lip profiles were significantly retracted. STL superimpositions revealed molar anchorage loss in both maxillary and mandibular arches exceeded clinically acceptable thresholds. The mesio-distal DPATM for linear values was significantly high(>0.5mm) for maxillary anteriors. Angular DPATM values differed significantly (>2.0$^0$) as well.

**Conclusions**: Cephalometrically the changes seen in premolar extraction cases using aligner therapy are comparable with changes reported in literature for fixed appliances. However, on STL model superimpositions, significant angular, maxillary anterior linear and anchorage loss DPATM values were observed.

## 4. Lingual orthodontics in an aligner world: "turbo boost" or "ghost driving"?

**Fotis Exarchou**
Private Practice (Ioannina, Greece)

**Aim**: The demand for aesthetic alternatives to labial braces in combination with the implementation of digital technology in orthodontics, resulted in an incredible growth in the number of aligner treatments in our every day's clinical practice. Although the digital technology had an impact on the customisation of lingual fixed appliances too, the number of treatments in this field of orthodontics was in fact not comparable to what is happening in the aligner field.

**Material and methods**: This presentation will focus on complex clinical cases and conditions, that would be challenging or even impossible to manage for a set of numerous aligners with or without the use of mandatory attachments and auxiliaries.

**Results**: The accuracy and predictability of a fixed lingual customised appliance, ensures a maximum of tooth control in every dimension, a crucial factor for the achievement of optimum results in complex cases. Aesthetic and functional demands can be fully accomplished in a truly invisible and independent from patient compliance way, a condition that is absolutely important when targeting clinical excellence and differentiation from

colleagues and general practitioners.
**Conclusions**: Lingual orthodontics is an absolute necessary tool in every day clinical practice. It combines the accuracy and predictability of a fixed appliance, with truly incomparable aesthetics. As orthodontists we have to keep in mind that our most powerful and aesthetic treatment option should differentiate from what general practitioners can provide with aligners. However, the choice is in our patients' hands, unless we give them the option to decide.

## 5. Covid-19 in practicing orthodontists in greece: reported cases and concerns

Michelaki E. Iris[1], **Douma Aikaterini**, Angelopoulos Gerassimos, Tsolakis Apostolos
[1]University of Athens, Athens, Greece
**Aim**: Herein, we aimed to present the impacts related to COVID-19 pandemic for practicing orthodontists in Greece.
**Materials & Methods**: Data were obtained through an anonymous online survey questionnaire, addressed by e-mail to practicing orthodontists in Greece during the first post-lockdown period (between July 20 and December 7, 2020). A sample of orthodontists (n=194, 35,1% of total practicing in Greece) participated. The questionnaire had six domains: (1) demographics, (2) symptoms/signs related to SARS-Cov-2 infection; (3) adherence to COVID-19 published guidelines; (4) psychological distress and behavioral adaptation; (5)practicing concerns faced during the pandemic; (6)adoption of orthodontic treatment procedures and novel modalities.
**Results**: Two confirmed COVID-19 cases (1,0%) were reported. The websites of Dental and Orthodontic Associations were reported as the source of information of the new guidelines. Major concerns included personal protective equipment (PPE)
Availability and increased cost. Level of anxiety of the orthodontists, during the peak of the pandemic was medium (mean ±SE: 4.97 ± 0.16) and inversely correlated to the age of the orthodontist. At re-opening, high level of perceived safety was recorded (mean ±SE: 7.4 ± 0.16). Tele-orthodontics were used (69,6%) to communicate with patients with aligners. 62,9% of the professionals felt that treatment with aligners resulted in fewer issues compared to braces.
**Conclusions**: Orthodontists in Greece are not at a greater risk for COVID-19 (1,0%) compared to the general population statistics (1,1%). Despite scarcity and increased cost of PPE, orthodontists adhered to the guidelines issued. COVID-19 pandemic encouraged the utilization of the advantages of tele-orthodontics. Aligner treatment revealed fewer issues and emergencies during and after the peak of the pandemic.

## 6. Can we really accelerate orthodontic tooth movement?

**Dr. Ahmed Elkalza**[1]
[1] Assistant professor of Orthodontics, Alexandria University, Egypt
Prolonged orthodontic treatment time is considered a major concern for the patient and the clinician. One of the primary goals of any orthodontist is to reduce orthodontic treatment time and increase patient satisfaction. Many methods have been assumed to decrease time of tooth movement by local or systemic administration of medicines, mechanical or physical stimulation

such as electric current, vibration and low- level laser. Surgical methods include corticotomy, piezocision and more recently micro-osteoperforation. Two clinical studies were conducted evaluating the effect of piezocision and micro-osteoperforation on the rate of orthodontic tooth movement and correlation between tooth movement and apical root resorption.

**Materials and Method**: A two group split mouth sample consisted of 10 patients with age range 16-25. In the 1st group, canine retraction was accelerated by piezocision and other side as control. In the 2nd group, canine retraction was accelerated using micro-osteoperforation and other side as control. CBCT scans were taken to evaluate apical root resorption in both groups.

**Results**: Canine retraction showed significant difference between test and control sides in both groups. There was significant difference regarding apical root resorption between the two groups. Conclusion: Piezocision and micro-osteoperforation showed clinical success in accelerating tooth movement, but piezocision was accompanied with apical root resorption in comparison to micro-osteoperforation

## 7. The impact of diabetes mellitus on orthodontic tooth movement

Damanakis Georgios, **Christopoulou Isidora**[1], Tsolakis Apostolos I.

[1] National and Kapodistrian University of Athens, Private Practice, Athens, Greece.

**Aim**: The purpose of this experimental study was to investigate the possible differentiation in biological processes involved in alveolar bone remodeling during the application of orthodontic forces in association with diabetes mellitus.

**Materials & Methods**: Twenty-six Wistar rats were used and divided randomly into two groups (experimental, control), consisting of thirteen animals each. The total experimental period was 28 days. In the first group (experimental) the rats became diabetic after an intravenous injection of streptozotocin, while in the second group (control) the rats remained non-diabetic. In both groups orthodontic force of 30 gr* was applied on the upper right first molar through a closed helical coil spring. Lateral and dorsoventral cephalograms were taken at the beginning and at the end of the experimental period. Impressions of both jaws were also taken. The distance between the upper right first molar and the central right incisor was measured in both groups. Histological and histochemical examination of the alveolar bone around the upper first molar was conducted for each animal. Photographs of the histologic specimens were taken and subjected to computational image analysis.

**Results**: Decreased osteocellular activity was observed in the group of diabetic animals and the difference between the two groups was statistically significant. The distance which the upper right first molar had accomplished was larger in the diabetic group, and the alveolar bone in the diabetic induced animals was found to be osteoporotic.

**Conclusions**: The results showed that diabetes mellitus affects the rate of orthodontic tooth movement, accelerating it, as well as the quality of alveolar bone remodeling.

## 8. Three-dimensional airway and skeletal changes with skeletally anchored fixed functional appliances: data from 2 randomized controlled trials

**Sherif Aly Mahmoud Elkordy**, Noha Orabi, Juan Martin Palomo, Yehya Mostafa.
Presenting author: Sherif Aly Mahmoud Elkordy. Affiliation: Lecturer of Orthodontics, Cairo University, Egypt.

**Aim**: To detect the three-dimensional changes in the total pharyngeal, oropharyngeal, nasopharyngeal airway volumes and skeletal changes after treatment with miniplates and mini-screw anchored Forsus Fatigue Resistant Device (FFRD).

**Methods**: A sample of 66 skeletal Class II growing females with deficient mandibles were randomly allocated into 4 groups; 15 subjects received FFRD and miniplates for direct anchorage of the appliance (FMP group), 17 received mini screws for indirect anchoring of FFRD (FMI group), 17 subjects received FFRD only (F group) & 17 were untreated controls. CBCT images were taken before appliance insertion & after removal. Paired t tests were used to compare treatment/ observation changes within each group. One Way Analysis of Variance was used for comparing the changes between the four groups.

**Results**: Total airway volume significantly increased in the FMP group together with a significant increase in the mandibular length and SNB angle as compared with the other groups. No significant changes in the airway volume and minimum constriction area were detected in the FMI and FFRD groups. A mild headgear effect was detected in the FMP when compared to FFRD group.

**Conclusions**: Addition of miniplate anchorage to FFRD resulted in increase in the airway dimensions and the mandibular skeletal outcomes. Conversely, indirect miniscrew anchorage was not able to induce a significant change in airway and mandibular dimensions.

## 9. Does surgically assisted maxillary protraction with skeletal anchorage and class iii elastics effect the pharyngeal airway?

Elvan-Onem Ozbilen[1], **Petros Papaefthymiou**[2], Hanife-Nuray Yilmaz[1], Nazan Kónókkeleş[3]

[1] Assistant Professor, Marmara University, School of Dentistry, Department of Orthodontics, Istanbul, Turkey

[2] Marmara University, School of Dentistry, Department of Orthodontics, Istanbul, Turkey

[3] Professor, Bezmialem Vakıf University Faculty of Dentistry, Department of Orthodontics, Istanbul, Turkey

**Aim**: To analyze the airway changes following surgically assisted maxillary protraction with skeletal anchorage and Class III elastics.

**Materials & Method**: The sample size consisted of 15 Class III patients with a mean age of 13.12 ± 1.28 years. Initially, growth changes were assessed for 5 months prior to treatment start. Airway and skeletal changes associated with control, pre-treatment, post-protraction, and follow-up periods, were monitored and compared.

**Results**: There were no statistically significant changes during the control period regarding the skeletal and airway parameters. During the maxillary protraction period, RP1-PNS, SNA, ANB, and FMA, increased significantly, while SNB angle did not show any significant change. No significant changes were seen during the maxillary protraction period regarding the airway parameters. There were no statistically significant changes in any skeletal and airway parameters in the follow-up, except for the FMA angle, which decreased significantly.
When the total treatment is evaluated in regard to airway parameters, only Ad2-PNS value increased significantly, whereas, concerning skeletal variables RP1-PNS, SNA and ANB presented a considerable increase.
**Conclusions**: No significant changes in skeletal and pharyngeal airway parameters were found during the control period. Although significant increases were found in skeletal parameters except for SNB following maxillary protraction, the pharyngeal airway dimensions' changes were insignificant. During the follow-up period, favorable skeletal changes were maintained, while there no significant changes occurred in pharyngeal airway dimensions.

## 10. Craniofacial characteristics in a family with osteogenesis imperfecta

**Kalliopi Siotou***, Isidora Christopoulou, Maria Georgaki, Apostolos I. Tsolakis
*Department of Orthodontics, National and Kapodistrian University of Athens, Greece
**Aim**: Osteogenesis imperfecta (OI) is a heterogenous group of connective tissue disorders that mainly manifest as bone fragility and skeletal deformity. In most families it segregates as a dominant trait and results from mutations in type I collagen genes. Dental malocclusions, probably relevant with the skeletal and dentoalveolar irregularities, are frequently seen on those patients. The aim of this study is to underline the craniofacial characteristics of patients suffering from this rare disease.
**Materials & Methods**: A family consisting of three members, mother and her two daughters, all diagnosed with osteogenesis imperfecta, sought treatment at the Orthodontic Department of the National and Kapodistrian University of Athens. The diagnosis of osteogenesis imperfecta was based on biochemical examination, included in the medical records provided by their treating doctor. The daughters had undergone previous orthodontic treatment, lasting ten years, at a private dental clinic in Albania. The evaluation of the patients included clinical and radiographic examination.
**Results**: In our sample all the patients had skeletal Class III pattern. They had also dental malocclusion problems that the conservative previous orthodontic treatment was unable to resolve. Skeletal discrepancies, open bite, cross-bite along with vertical underdevelopment of the dentoalveolar structures and the condylar process were presented.
**Conclusions**: Our findings confirm that the maxillofacial region is usually affected by osteogenesis imperfecta. The facial growth impairment is frequently seen in patients with osteogenesis imperfecta, and dentists should be aware of their complex dentoskeletal problems to manage them with appropriate techniques.

## 11. Maxillary expansion in patients with unilateral cleft lip and palate: digital dental casts analysis

**Scerra Melania Selene**,* Bencivenga Michele Stanislao, Carfora Marco, Grassia Vincenzo, Perillo Letizia
* Orthodontic Program, Multidisciplinary Department of Medical-Surgical and Dental Specialties, University of Campania Luigi Vanvitelli, Naples, Italy

**Aim**: Children with UCLP usually suffer from a nasomaxillary complex deficiency with upper dental arch constricted which continues worsening until the end of their growth. Thus, it is suggested to begin an early dentofacial orthopedic treatment protocol during the mixed dentition with a palatal expander.

Thus, the aim was to compare the upper arch dimensions of young patients with unilateral cleft lip and palate (UCLP) before and after treatment with bonded maxillary expander and hybrid activation protocol using digital dental casts.

**Materials & Method**: Sixteen subjects with UCLP, aged between 7 and 14 years (mean age 10.9 ± 2.7 years) consecutively treated with bonded maxillary expander and hybrid activation were included. The dental casts before and after treatment were digitalized using a 3Shape scanner. Intercanine, interpremolar and intermolar widths (at cusp and gingival levels) and arch perimeters were measured. The significance level for statistical analyses was set as $p < 0.05$.

**Results**: The total sample included 16 patients, 10 females and 6 males. The initial mean age was 10.9 ± 2.7 years. The total treatment phase with the bonded expander (T0-T1) lasted 12.0 ± 1.9 months while the active expansion phase was 4.0 ± 0.2 months. Comparing measurements at T0 and T1 showed statistically significant improvements in all transverse arch widths while arch perimeter values revealed no significant outcomes.

As to the different arch diameters at both cusp tips and gingival levels, data showed statistically significant results only for the diameter 3-3.

**Conclusions**: The use of a bonded maxillary expander with a hybrid activation protocol during growth may be efficient to improve all transverse upper arch widths in patients affected by UCLP.

## 12. Early treatments of dentoskeletal class III malocclusion: modified sec iii versus rme/fm

**Chiarenza Maria Chiara**,* Schiavone Maria Grazia, Carrino Rossella, Franchi Lorenzo, Perillo Letizia
* Orthodontic Program, Multidisciplinary Department of Medical-Surgical and Dental Specialties, University of Campania Luigi Vanvitelli, Naples, Italy

**Aim**: Early treatments of Class III dentoskeletal disharmonies aim at controlling jaw growth along with dentoalveolar modification and correction of the eventual negative overjet. The objective of this retrospective observational study was to compare the short-term cephalometric outcomes of the protocols modified splints, Class III elastics, chincup (mod SEC III) and rapid maxillary expansion and facial mask (RME/FM) for the early treatment of growing subjects with Class III malocclusion.

**Materials & Methods**: A total sample of 51 subjects with anterior crossbite or edge-to-edge incisor relationship, Class III molar relationship, Wits appraisal of ≤ 2 mm and ANB ≤ 3 degrees and prepubertal skeletal maturation (CS1

or CS2) were included. The sample was evaluated before (T1, mean: 7.9; SD: 1.0) and at the end of treatment (T2, mean: 9.0; SD: 1.0). Digital initial and intermediate lateral cephalograms were evaluated. Statistical comparisons between the two groups were performed with independent sample t tests.
**Results**: The modified SEC III sample included 20 patients (11 males and 9 females, mean: 7.9 years; SD: 4.2) while RME/FM group was composed of 31 patients (16 males and 15 females, mean 6.9 years; SD: 4.2). The length of the modified SEC III protocol ranged between 9-15 months (mean: 12.0 years; SD: 4.2), whereas the length of the RME/FM ranged between 9-21 months (mean: 13.1 years; SD: 2.6).
Both the modified SEC III and the RME/FM sample groups showed significantly favorable effects in terms of maxillary advancement (SNA 1.3° and 1.5°), control of mandibular projection (SNB -0.5° and -0.8°) and intermaxillary relationships (ANB 1.8° and 2.3°; Wits 3.4 and 1.9 mm). The modified SEC III group showed a statistically significant greater control in the intermaxillary divergency considering the SN to Pal. Pl. ($P < 0.006$) and Pal. Pl. to Mand. Pl. angle ($P < 0.002$) with a difference of 2.3 mm between the groups.
**Conclusions**: Early treatment of growing patients with dentoskeletal Class III disharmonies is efficient using either modified SEC III or RME/FM protocols. However, a higher vertical control is achieved with the modified SEC III.

## 13. Dilemmas and treatment options of borderline cases in orthodontics

**Vasileios D. Evangelidis**, Aikaterini Papadimitriou, Moschos A. Papadopoulos
Department of Orthodontics, Faculty of Dentistry, School of Health Sciences, Aristotle University of Thessaloniki, Thessaloniki, Greece
**Aim**: There are always different pathways to reach the desirable treatment goals in a borderline case. The selection of the treatment depends on different factors. Aim of this presentation is to highlight these aspects by means of two cases treated in an alternative way than the conventional one.
**Subject and Methods**: The first patient was a 21-years old male. He presented with Class III malocclusion, anterior and bilateral posterior open bite, severe crowding of the upper and lower dental arch. Furthermore, the upper first molars were missing. The treatment dilemma was either to procced with orthognathic surgery or a camouflage treatment. The patient rejected the surgical treatment and thus a conventional orthodontic was followed.
The second patient, a 13-years old female, presented with Class II malocclusion, bilateral crossbite, and severe crowding in the upper and lower dental arch. The treatment dilemma was to follow either a protocol involving Rapid Palatal Expansion (RPE) and extractions of the four premolars or RPE without extractions. The patient preferred the second option, which was also followed.
**Results**: The overbite, the open-bite (first case), the crossbite (second cases) and the crowding were corrected, and was achieved a Class I malocclusion, normal overbite and overjet, without any side effects to the anchor teeth or the surrounding tissues.
**Conclusions**: These alternative ways of treating seem to be effective and produce a desirable aesthetic and functional result.

## 14. Impaction of maxillary canines and its effect on the position of adjacent teeth and canine development: a cone-beam computed tomography study

**Nucci Ludovica***, Dekel Eyal, Flores-Mir Carlos, Perillo Letizia, Chaushu Stella
*Orthodontic Program, Multidisciplinary Department of Medical-Surgical and Dental Specialties, University of Campania Luigi Vanvitelli, Naples, Italy

**Aim**: The purposes of this study were to characterize the 3-dimensional position of teeth adjacent to impacted canines and examine whether impaction affects canine development using CBCT.

**Materials & Method**: CBCT images of 34 unilateral maxillary impacted canines (12 males, 22 females; mean age, 16.5 years) were collected. 21 canines were palatally impacted (PIC), and 13 were buccally impacted (BIC). Angular measurements of lateral incisors (LIs), first premolars, and the impacted canines positions relative to a 3-dimensional coordinate system and canines' volume, length, and shape of the roots, were compared between the affected and contralateral control sides. The influence of canine position and severity of impaction was examined. Statistics included the paired t test, Wilcoxon signed rank test, and McNemar test.

**Results**: In the PIC group, LIs showed significant mesiobuccal rotation (17.1°), mesial angulation (8.4°), and buccal root torque (5°) and first premolars mesiobuccal rotation (6.1°). In the BIC group, LIs displayed mesiobuccal rotation (18°) and significant palatal root torque (5°). The canine volumes were similar in BICs and smaller in PICs. The lengths were shorter in both, but root hooks were more prevalent in BICs. The severity of impaction affected the variables.

**Conclusions**: The differential position of the adjacent teeth is pathognomonic for PIC vs BIC, and impaction seems to affect canine development. The findings provide evidence-based clinical and radiographical clues for early diagnosis of canine displacement and planning the most efficient treatment strategy. In addition, they support timely orthodontic eruption before the development of the apical third of the root.

## 15. Impacted maxillary canine and associated dental anomalies. A retrospective study

**Athanasia-Eirini Zarkadi**[1], Despoina Balli[2], Olga-Elpis Kolokitha[3]
[1] DDS, Dental Practice, Nicosia, Cyprus.
[2] DDS, Dental Practice, Thessaloniki, Greece.
[3] DDS, MSD, PhD, Associate Professor, Department of Orthodontics, Faculty of Dentistry, School of Health Sciences, Aristotle University of Thessaloniki, Greece

**Aim**: To evaluate the significance of association between maxillary impacted canines and various dental anomalies.

**Materials & Methods**: Files of 874 orthodontic patients were examined for the presence of maxillary impacted canines. From this sample a group of 97 patients (39 males and 58 females) with at least one impacted maxillary canine consisted the study group. This group was compared to a control group of 97 patients (42 males and 55 females) that was created by random selection from the initial sample without maxillary canine impaction. The impaction diagnosis was made from the panoramic radiographs and confirmed from the surgery. The association between maxillary canine

impaction and dental anomalies was examined with the chi-square test. A classification tree was created to further investigate the relations between impaction and dental anomalies. The reproducibility of diagnoses was assessed by re-examining the records of 25 patients two weeks after the first examination. Reproducibility was 100% for all variables.
**Results**: Statistically significant difference was found for peg-shaped maxillary lateral incisors and infraoccluded deciduous molars. The presence of a peg shaped upper lateral incisors arises the probability of an impacted canine to 83.3%, a distal displaced unerupted second premolar to 63,16% and the impaction of any other teeth to 80% as showed the classification tree.
**Conclusions**: The presence of peg-shaped maxillary lateral incisors and infraocclusion of deciduous molars can be considered valuable early risk indicators for maxillary canine impaction because they manifest before the maxillary canine eruption.

## 16. Are chin and symphysis morphology facial type dependent? A ct-based study

**Tatiana Sella Tunis** a,b,c, Rachel Sarig, Alexander Dan Vardimon, Israel Hershkovitz and Nir Shpack.
a) Department of Orthodontics, The Maurice and Gabriela Goldschleger School of Dental Medicine, Tel Aviv University, Ramat Aviv 69978, Israel
b) Department of Anatomy and Anthropology, Sackler Faculty of Medicine, Tel Aviv University, Ramat Aviv 69978, Israel;
c) Shmunis Family Anthropology Institute, Dan David Center for Human Evolution and Biohistory Research, Tel Aviv University, Ramat Aviv 69978, Israel;

**Aim**: The chin is a major determinant of the facial profile; hence, it plays a major role in orthodontics and orthognathic surgery. It is thus essential to follow and better understand its expression in different facial types. The major objectives of the current study were to characterize morphometrically the chin and symphysis and reveal their association with different facial types.
**Materials & Methods**: Computed tomography scans of the head and neck of 311 adult individuals were utilized: 163 males and 148 females, aged 18-95 years old. Individuals were classified into three facial types (short, average, and long). Height, width, projection, inclination, thickness, and area were measured on the chin and symphysis.
**Results**: The majority of the population (70%) manifested an average facial type; the other 30% were almost equally distributed between short and long facial types. The long facial type was more common among females and the short facial type among males. Chin projection, area and size were significantly greater in short-faced individuals. Chin width in males was similar for all facial types whereas in females, chin width was the widest in the short facial type and the narrowest in the long facial type. Symphysis height was significantly greater in long-faced individuals in both sexes. The lower incisors' inclination relative to the mandibular plane was not significantly associated with the chin or symphysis morphology.
**Conclusions**: Chin and symphysis morphology is facial type dependent. Orthodontists and maxillofacial surgeons should be aware of the complex relationship between facial types and chin/symphysis size and shape when planning treatment.

## 17. Variation in chin and mandibular symphysis size and shape in males and females: a ct-based study

Tatiana Sella Tunis, Israel Hershkovitz, Alexander Dan Vardimon, Rachel Sarig, and **Nir Shpack**[1]
[1] Department of Orthodontics, The Maurice and Gabriela Goldschleger School of Dental Medicine, Sackler Faculty of Medicine, Tel Aviv University, Ramat Aviv, 69978

**Aim**: The chin is a unique anatomical landmark of modern humans. Its size and shape play an important role from the esthetic perspective. However, disagreement exists in the dental and anthropological literature regarding the sex differences in chin and symphysis morphometrics. The "sexual selection" theory is presented as a possible reason for chin formation in our species; however, many other contradictory theories also exist. This study's aims were therefore to determine how chin and symphysis size and shape vary with sex, and to discuss "sexual selection" theory as a reason for its formation.
**Materials & Methods**: Head and neck computed tomography scans of 419 adults were utilized to measure chin and symphysis sizes and shapes. The chin and symphysis measures were compared between the sexes using an independent-samples t-test, a Mann–Whitney test, and the F-statistic.
**Results**: The chin width was significantly greater in males than in females ($p<0.001$), whereas the chin height, area, and size index were significantly greater in females ($p<0.001$). Symphysis measures did not differ significantly between the sexes. Size accounted for 2–14% of the chin variance and between 24–33% of the symphysis variance.
**Conclusions**: Overall, the chin was found to be a more heterogeneous anatomical structure than the symphysis, as well as more sexually dimorphic.

## 18. Computer guided neurotoxin injection in hyperactive lip (gummy smile)

**Islam Kassem, FDS RCS1**
1Consultant Maxillofacial Surgeon, Alexandria University Hospital, Egypt

Gummy smile exhibit a challenge for both assessment and management, multiple modalities of treatment such as neurotoxin injection
Neurotoxin is not proved a safe methods till now
The author shows his follow up of his methods 4 years experience of computer guided injection to enhance more safety in injection
Pit falls of techniques is discussed in details

## 19. A systematic diagnostic scheme for excessive gingival display “gummy smile”

**Dalia El-Bokle, DDS, MSc, PhD**[1], Amany Hassan Abdel Ghany, DDS, MSc, PhD.[2]
[1] Diplomate of the American Board of Orthodontics, Former professor of Orthodontics (Cairo University), Consultant of Orthodontics, Zayed Orthodontics, Giza, Egypt.
[2] Assistant professor of Orthodontics, Cairo University

Achieving a harmonious smile and improving smile esthetics has become an integral part of orthodontic treatment nowadays. Excessive gingival display or gummy smile "GS" negatively affects smile esthetics and often prompts patients to seek orthodontic treatment. Therefore, treatment of GS has become a prime objective in response to patient demand. The manifestation

of GS could be caused by various etiological factors. Differentiating the underlying etiology(ies) for each case of GS is essential for making an accurate diagnosis and an optimal treatment plan.
The aim of this article is to present a comprehensive diagnostic scheme of GS comprising 7 sequential steps to quantitatively distinguish the possible contributions of related etiologies. A table format including the norms for each measurement is presented to help clinicians gather the necessary information for easy reference and a clinical case is also presented with the applied diagnostic scheme.

## 20. Comparison of biomechanical and surface characteristics of retrieved orthodontic mini screws of three commercially available brands - an in vivo study

**Dr.Ajit Kalia**
Prof. & Chair, M.A. Rangoonwala College of Dental Sciences

**Aim**: Relocation of mini-screw is sometimes required at various stages during orthodontic treatment due to anatomical limitations and interferences.
The study was conducted to analyze and compare the morphology and surface characteristics of 3 commercially available brands of mini-screws before and after clinical use, and check their viability for reinsertion during the relocation process.
**Materials & Method**: Mini-screws of three commercially available brands were evaluated for the sharpness of their threads and active tip, surface roughness and surface chemical composition using SEM-EDS before and after clinical use.
**Results**: The mean pre-insertion sharpness of threads did not differ significantly compared to mean post retrieval values in Group I, II and III. In Group II and Group III, the mean post-insertion α value is significantly higher compared to mean pre-insertion α value. The SEM images obtained post insertion revealed generalized loss of gloss and surface finish with a consequently dull appearance in all the groups, but most evident in Group I. EDS analysis post retrieval shows an increase in the amount of organic elements such as carbon and oxygen in groups II and III.
**Conclusions**: Mini-screw reuse within the same patient maybe possible provided proper recycling procedure has been followed and careful pilot drilling is done to overcome the decreased cutting ability of the tip due to deformation.

## 21. Missing upper central incisor: case presentations and treatment options

Gerassimos Angelopoulos[1], **Christina Pratikaki**[2]

**Aim**: Although infrequent (0,2% congenitally missing, more often lost due to trauma, ankylosis, root resorption or tooth decay), the absence of an upper central incisor presents challenges to the clinician. The aim of this study is to review alternative treatment options and present two cases treated in our orthodontic clinic.
**Materials & Methods**: In total, fifty-five clinical cases have been found from the review of the literature. The patient population included cases with
a) congenital absence, b) trauma, c) ankylosis, d) SMMCI syndrome,
e) impacted tooth and f) bilateral absence of both incisors. From our clinic, in the first case the incisor was lost due to trauma and in the second due

to decay, endodontic treatment and subsequent root resorption.
**Results**: Two are the main treatment options: a) maintenance of the edentulous diastema and b) orthodontic closure. Each one of the two groups includes numerous subcategories, such as, prosthetic rehabilitation, autotransplantation, etc. Twenty-one out of fifty-five published cases were treated with maintenance of the diastema, whereas in thirty-four cases treatment was performed through orthodontic space closure. In both of our clinic patients we opted for space closure with centralization of the lateral incisor and lateralization of the canine. In all cases, the orthodontist had to collaborate with the reconstructive dentist and in few cases with the periodontist, endodontist and/or oral surgeon.
**Conclusion**: Missing central incisor cases, regardless of the opted treatment plan require a multidisciplinary approach among dentists of different specialties. In particular, the role of the orthodontist, the periodontist and the general practitioner/prosthodontist is vital in order to reassure the success of the treatment. The optimal treatment plan depends on the distinctive clinical parameters along with the patient's budget and aesthetic preferences.

## 22. Relapse one week after bracket removal: a 3d superimpositional analysis

**Alexandros Papagiannis**, Despina Koletsi, Demetrios J Halazonetis, Iosif Sifakakis
Presenting Author Affiliation: Department of Orthodontics, School of Dentistry, National and Kapodistrian University of Athens, Greece; Private Practice in Orthodontics, Lamia, Greece
**Aim**: The objective of this study was to measure tooth movement one week post-treatment and assess potential correlation with changes invoked during treatment.
**Materials & Method**: Thirty-eight patients were included in this study (19 males, 19 females). Polyvinyl-siloxane impressions were taken after debonding and one week later, and digitally scanned in 3-dimensions. During this period, no retention method was implemented. The digital casts were superimposed on structures of the hard palate mucosa. Movements of the maxillary first molars, canines and central incisors were evaluated between three time points (T0 – pre-treatment, T1 – after debonding and T2 – one week post-treatment). The Spearman correlation coefficient was used to investigate the correlation between the post-treatment relapse (T1-T2) to tooth movement during treatment (T0-T1).
**Results**: Relapse was detected and reflected changes in tooth position during treatment. For the first molars (right, left) the correlation between treatment and post-treatment tooth movement was confirmed in the transverse direction (r=-0.38, P=0.020; r=-0.32, P=0.052), tipping (r=-0.40, P=0.015; r=-0.34, P=0.034) and the anteroposterior direction (r=-0.31, P=0.061; r=-0.36, P=0.027); for the canines (right and left), as rotation around their long axis (r=-0.55, P=0.003; r=-0.58, P=0.002); for central incisors (right and left) in the anteroposterior direction (r=-0.55, P=0.000; r=-0.48, P=0.03), transverse direction (r=-0.43, P=0.07; r=-0.32, P=0.047), and rotation around their long axis (r=-0.53, P=0.001; r=-0.28, P=0.089).
**Conclusions**: Post-treatment changes in tooth position were mostly related to tooth movement during treatment; these correlations may help clinicians predict short-term relapse, evaluate long-term retention need and design individualized retention schemes.

## 23. Effect of zygosity on vertical, sagittal and airway growth in a twin sample: a longitudinal study

**Sofia Sideri***, Ahmed Alsulaiman, Leslie Will, Melih Motro
*Boston University, Henry M. Goldman School of Dental Medicine, Department of Orthodontics and Dentofacial Orthopedics, Boston, Massachusetts, U.S.A.

**Aim**: The aims of this study in growing monozygotic (MZ) and dizygotic (DZ) twins were to explore the influence of zygosity on vertical, sagittal and airway growth and to assess the correlation between skeletal and airway cephalometric measurements two years after peak growth.

**Materials & Methods**: This longitudinal study used data from 35 MZ and 35 DZ untreated pairs from Forsyth study, at Boston (1959-1975). Lateral cephalograms were collected and analyzed between the age of 6-18 years, at 5 consecutive time points, according to skeletal maturation index (SMI), using OrthoDx® and ImageJ® software. Zygosity and gender, skeletal and airway cephalometric measurements were analyzed with mixed effect models and Pearson correlation coefficient. Statistical significance was set at $p<0.05$.

**Results**: A total of 140 subjects were included in this study (50% MZ and 50% DZ). A year of increase in age had a significant effect on several vertical, sagittal and airway growth measurements ($p<0.05$ - $p<0.0005$). DZ twins had greater difference on vertical, sagittal and airway than MZ ($p<0.05$ -$p<0.0005$). Significant correlation of skeletal to airway variables was mostly observed for the DZ, MZ, male and female group ($p<0.05$ - $p<0.0005$). Heritability varied for skeletal and airway measurements ((1.6%-87.6%).

**Conclusions**: This study provided evidence for zygosity contribution to the complex vertical, sagittal and airway growth and the relationship of skeletal and airway cephalometric measurements. High heritability was shown for upper and lower airway area and upper airway width.

## 24. Temporomandibular disorders and rheumathoid arthritis: correlation with serology

**Rotolo Rossana Patricia,*** Nucci Ludovica, Fanuzzi Federica, d'Apuzzo Fabrizia, Perillo Letizia
* Orthodontic Program, Multidisciplinary Department of Medical-Surgical and Dental Specialties, University of Campania Luigi Vanvitelli, Naples, Italy

**Aim**: Rheumatoid Arthritis (RA) is a systemic and chronic autoimmune disease with persistent inflammation at the synovial joints causing morphological deformities and pain. RA may severely affect the normal functions of temporomandibular joints (TMJ) in a range from 45% to 92.8%. of adults.
The main clinical signs of the TMJ involvement with RA are arthralgia, stiffness during mouth opening and joint noises and limited functions upon waking. Early diagnosis, treatment and monitoring of TMJ disturbances should be extremely important for patients' quality of life.
The aim of this study was to evaluate the prevalence of TMJ disorders (TMD) in patients with RA and their eventual correlation with serology.

**Materials & Method**: The study group consisted of 17 patients (2 males and 15 females) with diagnosed RA aged between 36 and 76 years.
The exclusion criteria were incomplete medical records, congenital or acquired facial anomalies, previous maxillofacial surgery or orthodontics.
A questionnaire was delivered to each patient to ask if they suffered of any TMD (joint sound, locking, or functional limitations). A clinical evaluation was performed and dental casts, panoramic x-rays and serological analysis

were collected. In particular, rheumatoid factor (RF), C-reactive protein (CRP), erythrocyte sedimentation rate (ESR), immunoglobulin M-RF, anti-CCP antibody and anti-nuclear antibody (ANA) were evaluated.
**Results**: The symptoms at the TMJ reported in patients with RA were tenderness/pain in the joint area (arthralgia) in 64,7%, joint sounds in 47,0% and myofascial pain in 64,7%.
High positive RF showed a significant correlation with the presence of TMD (60%). The anti- CCP antibody and ANA were positive in 40% while CRP and ESR showed high levels in 46,7% of patients with TMJ derangements.
**Conclusions**: RA seems to play a role in TMD with a higher frequency of patients' complaints.
Moreover, all the serological tests, in particular the RF, showed a strong correlation with the presence of TMJ disorders. Further investigations should be performed in a wider sample.

## 25. The role of b-cells in orthodontic tooth movement

**Gilad Mizrahi**1, Yehuda Klein1, Omer Fleissig2, Stella Chaushu2
1Institute of Dental Sciences, 2Dept of Orthodontics, The Hebrew University, Faculty of Dental Medicine, Jerusalem, Israel.
**Aim**: We aim to elucidate the involvement of B-cells and their molecular mechanism of action in orthodontic tooth movement (OTM).
**Materials & Methods**: Ni-Ti springs were set between the upper first molar (M1 mesial shift) and upper incisor of C57BL/6 male mice. Two groups were compared: CD19cre homozygote and WT (control). OTM distance and was measured using μCT scanner. Osteoclasts-like cells and B-cells were evaluated using TRAP and immunofluorescence staining, respectively. Additionally, RNA sequencing analysis was employed in order to determine the impact of B-cells ablation on the gene expression profile in the force-subjected periodontal tissues.
**Results**: 14 days following force application CD19cre mice presented a significant reduction of 28% in OTM rate ($p<0.0001$) and 37% in TRAP+ cells around the compressed alveolar bone ($p<0.001$). Moreover, numerous CD19+ B-cells were found in the alveolar bone of the WT mice following 3 days of OTM. The RNA sequencing analysis exhibited a distinct down-regulation of genes associated with bone physiology, B-cells homing and action in aseptic inflammation and pro-inflammatory chemokines; and upregulation of genes associated with OB differentiation and negative regulators of immune response. RT-PCR validation confirmed the RNA sequencing results.
**Conclusions**: Collectively, the current findings suggest that B-cells and their CD19 receptor play a role in the immune processes underlying the bone remodeling of OTM. This data is supported by the genetic analysis which indicate that B-cells contribute for both inflammatory and bone response pathways associated with force application. These results add "new pieces for the puzzle" in the role of adaptive immunity and B-cells in OTM.

## 26. Frictional forces generated by the wedgewise system compared to edgewise appliances under conditions of simulated crowding

Panagiotis Michailidis, **Moshe Davidovitch**, Nir Shpack, Richard Iverson
Tel Aviv University - Maurice and Gabriela Goldschleger School of Dental Medicine

**Aim**: To compare the frictional force of a 5-bracket segment of the unique slot geometry presented by the TRIAMONDTM system compared to commonly used edgewise appliances under conditions of simulated dental crowding and with several arch wire types.

**Materials & Method**: A universal testing machine with computerized monitoring was used to draw straight lengths of nickel titanium and stainless steel arch wires through 5 sequential brackets of edgewise (Victory [Unitek], Damon 3 [Ormco], Flare [Adenta]), and a wedgewise system (TRIAMONDTM [Adenta]). The x/y-plane orientations of alternating brackets and wire shape/size/alloy were varied. Descriptive statistics, including means, standard deviations and 2-sample t-test ($p < 0.01$) were calculated for each specific bracket-wire-deflection combination (1056 trials).

**Results**: The unique slot geometry of the TRIAMONDTM system was found to cause 2.5-3.5 times less friction using "working" wires

**Conclusions**: The less horizontal and vertical discrepancy between brackets and the smaller the arch wire size, a rigid door/clip passive SLB expresses less friction. The more horizontal and vertical discrepancy between brackets and the larger the arch wire size, a non-rigid door/clip passive SLB expresses less friction. Friction varies according to ligation type, alloy composition and wire size/shape.

## 27. Immunotherapy based nanotechnology: cytokine nanoparticles for controlled bone remodeling in orthodontics

**Yehuda Klein**[1,2], Noy Pinto1, Omer Fleissig[2], Yechezkel Barenholz[1]*& Stella Chaushu[2]*.

[1]Department of Biochemistry, Institute for Medical Research Israel-Canada, Hebrew University-Hadassah Medical School.

[2]Department of Orthodontics, Hebrew University-Hadassah Faculty of Dental Medicine, Israel

Introduction: Pharmacological approaches to control orthodontic tooth movement (OTM) are limited due to lack of knowledge of the underlying biological mechanisms and rapid flush out of drugs by blood circulation, dictating frequent injections. Here, we aimed to identify pivotal molecular players in bone remodeling (BR) and OTM and develop a novel sustained release drug delivery system (DDS) based on combined immunotherapy and nanotechnology.

**Materials & Methods**: Gene-profiling was performed by RNA-sequencing in C57BL/6 mice OTM model for 1,3,7 and 14-days. In-vitro: RANKL was loaded in florescent-liposomes' and embedded in hydrogel (RANKLsome). RANKLsome imaging was performed by TEM and encapsulation efficiency(EE) and release profile by ELISA. Bioactivity and cytotoxicity were evaluated in BMM cells by TRAP-staining and XTT. In-vivo: RANKLsomes were injected around M1. RANKL pharmacokinetics was assessed by immunofluorescence staining and liposomes by IVIS. 14-days after force application, OTM and femora bone changes (systemic-effect) were evaluated by μCT, Ocs by TRAP-staining and Ocs gene markers by qRT-PCR.

**Results**: In-vitro, RANKL was efficiently-encapsulated in liposomes (76%) and released up to 14-days, with neither cytotoxicity nor loss of bioactivity. In-vivo, single injection of RANKLsome released RANKL for significantly longer period than free RANKL (6 vs. 1-day). IVIS showed liposomes presence at

least 9 days. RANKLsome accelerated OTM in comparison to free-RANKL and saline groups (x2.3, x1.3, x1, $p<0.05$), correlating with an elevation in Ocs-numbers and gene markers. No systemic effect was observed.
**Conclusions**: The OTM gene expression discoveries were successfully implemented in developing a novel DDS which enhances local BR and accelerates OTM, via a combination of immunotherapy and nanotechnology.

## 28. Accuracy of artificial-intelligence (ceph-x) computer generated landmarks in cephalometrics

Liat Abramovicz, **Ofer Sarne**, Moshe Davidovich, Tanya Sella-Tunis
**Aim**: The aim was to study the accuracy and reliability of artificial intelligence derived compared to practitioner delineated localization of lateral cephalometric landmarks.
**Materials & Method**: 10 pre-treatment digital lateral cephalometric radiographs were randomly selected from a university post-graduate clinic. 21 hard and soft tissue landmarks were identified by 6 specialists, 19 residents, 4 imaging technicians, and with CephX (Orca Dental, Hertzylia, Israel) which utilizes a convolutional neural network. Wilcoxon test was performed on 21 x,y coordinate pairs (i.e. 42 points) to determine the agreement between human and computer landmark identification.
**Results**: 6 x or y coordinates (14.28%) were found to be statistically different, with only 1 being outside the 2mm range of acceptable error, and 97.6% of coordinates were found to be within this range.
**Conclusions**: The use of CephX cephalometric landmark identification was found to be highly accurate and can serve as an aid in orthodontic diagnosis.

## 29. Overcoming barriers during ankylosis: combining orthodontics with corticotomy

**Aikaterini Papadimitriou**, Vasileios Dontsos, Athina Chatzigianni, Moschos A. Papadopoulos
Department of Orthodontics, Faculty of Dentistry, School of Health Sciences, Aristotle University of Thessaloniki, Thessaloniki, Greece
**Aim**: Ankylosis of impacted teeth during orthodontic traction could cause unexpected situations during treatment. Objective of this presentation is to discuss this problem by comprehensively presenting two patients treated with corticotomy to solve ankylosis.
**Subject and Methods**: Patient #1 was a 14-year-old male presented with Class III malocclusion and increased mandibular gonial angle, bilateral posterior open bite, and severe space loss for the eruption of the upper right second premolar. Patient #2 was a 16-year-old male with Class II malocclusion, increased down third of the face, and severe space loss for the eruption of upper right canine.
The treatment plan for both patients included a Quad-helix for palatal expansion and maximum anchorage during the traction of the impacted teeth. Once expansion was achieved, surgical exposure and tracking of the impacted teeth began, but no sign of eruption was evident even year one after. Thus, it was decided to perform corticotomy in order to likely enhance the eruption. In the first patient, full eruption was achieved 11 months later, while in the second, an additional corticotomy had to be done to achieve a successful treatment outcome.
**Results**: Following the proper biomechanical principles and taking advantage

of the corticotomy approach, efficient traction of the impacted teeth was possible, without any side-effects to the anchor teeth or the surrounding soft and hard tissues.

**Conclusions**: The implementation of corticotomy for the management of unexpected ankylosis of impacted teeth during traction seems to be an effective approach for satisfactory functional and esthetic outcomes.

## 30. Digital indirect bonding in orthodontics

**Shereef Shahen**
University of Campania Luigi Vanvitelli: Universita degli Studi della Campania Luigi Vanvitelli

Indirect bonding (IB) was introduced 50 years ago to reduce chair time. The main challenge was improving bonding materials. It was found that accuracy is nearly the same in both direct and indirect bonding and even the bond strength. The major development happened when digital technology became available and three-dimensional printer was invented. It has started only as planning, simulation and patient education. Now it is possible to have fully digital workflow. Although the manual and digital indirect bonding (DIB) were found to have nearly the same accuracy, the digital tech has saved chair time and has a promising future. DIB till now is still operator dependent, so carful identification is mandatory for accurate DIB. Traditional digital indirect bonding using rigid transfer tray is suffering from some defects: washing of composite during insertion occlusally, bracket play inside tray in case of crowding, undercut removal was unavoidable and possibility of bracket falling because of uncovered gingival parts of the brackets. So, a new transfer tray was developed called Shahen-DIB. In this new design the transfer tray was segmented to lingual bracing transfer tray and buccal segments that can be guided by teeth anatomy and lingual transfer tray. Buccal transfer trays can be for single or multiple teeth depending on buccal path of insertion. This helped to avoid the previous disadvantages.

**«The best oral presentation will be awarded»**

# E-POSTERS

## 1. The biomechanics of aligner orthodontics in cases with increased vertical dimension

**Dafni Doukaki DDS**, MSc, Mattheos Sanoudos DDS, PhD

**Aim**: The aim of this presentation is to present the unique properties of aligners when used in the treatment of open bite cases.

**Materials & Methods**: In this lecture cases that were treated with Invisalign appliance from a private practice in Athens will be presented.

**Results**: Some of the most challenging orthodontic cases have increased vertical dimension as the major component of difficulty. It has been a well-documented fact that cases with hyper-divergent planes are notoriously difficult to treat and many times the stability of the final result is questionable. In many of these cases extra oral appliances (high pull headgear) or TADS are also needed to ensure an acceptable result. The reason is that this type of appliances facilitates intrusive movements which are essential for a successful outcome.

Soon after aligners became a popular appliance in orthodontics, clinicians started to observe that they demonstrated certain advantages in the treatment of "high angle" cases. One of the reasons is that aligners often act as splints, allowing the differential extrusion of certain teeth. Moreover, they convert the forces of mastication into intrusive forces that can be directed to en-masse or sequentially intrude teeth.

**Conclusions**: The treatment planning process when aligners are used varies from conventional orthodontics. Various clin-checks will be analyzed with emphasis on the strategies employed that are unique on aligner orthodontics.

## 2. Gender distribution trends of orthodontists in greece from 1988 to date

**Alice Angelopoulos**[1], Gerassimos Angelopoulos[2], Vassilios Stathopoulos[3]

[1] Undergraduate student, European University of Cyprus

[2] Research associate, Department of Orthodontics, National and Kapodistrian University of Athens, Greece

[3] Orthodontist, private practice

**Aim**: To identify trends of gender distribution of Orthodontists in Greece from 1988 -when orthodontic specialty was officially recognized - until 2020. Additionally, gender distribution in postgraduate students and faculty members was recorded.

**Materials & Method**: The records kept in the secretariat of the Greek Association for Orthodontic Study and Research crosschecked from 1988 until 2020 with the records of the Hellenic Dental Association and the Dental Societies throughout Greece (verified thrice) were used. Five datasets of gender distribution, from 1988 until 2020, were analyzed. Students and faculty gender distribution in both Orthodontic Departments of Athens and Thessaloniki were recorded.

**Results & discussion**: Out of a total registered 552 practicing orthodontists in Greece 43,84% are women (December 2020). The percentage of female orthodontists gradually increased to become more balanced (1988: 31,4%, 1997: 32,54%, 2001:3 5,74%, 2005: 38,12%). Indeed, from 2001 until today, female orthodontists outnumbered their male colleagues with 53,84% females entering orthodontic practice. Today, 53,33% of the Orthodontic

postgraduate students in University of Athens and Thessaloniki are women. In regard to faculty from both Orthodontic Departments the current distribution is 50% women (more balanced compared to all faculty Departments from both Greek Dental Schools which is 34,81%).

**Conclusions**: In Greece, especially in Orthodontics, it seems that the trend of the last decades is more and more women to become orthodontists. During the last 20 years females entering orthodontic practice outnumber their male colleagues.

## 3. Prevalence of tooth agenesis in non-syndromic orofacial clefts: associations with cleft type and sex

Konstantonis Dimitrios, **Athanasiou Maria**, Vasileiou Dimitrios, Nassika Maria, Vastardis Heleni
Department of Orthodontics, School of Dentistry, National and Kapodistrian University of Athens, Athens, Greece.

**Aim**: The aim of this study was to investigate the prevalence of tooth agenesis in association with sex and cleft type in a spectrum of non-syndromic orofacial cleft patients.

**Materials & Methods**: Intraoral records and radiographs of 183 orofacial cleft patients (115 males and 68 females) were examined for tooth agenesis. All records were obtained from the Graduate Clinic of the Departments of Orthodontics and Pediatric Dentistry of the School of Dentistry of the National and Kapodistrian University in Athens, Greece. The statistical analysis included Fisher's exact tests as well as logistic regression to assess any mutual effects of sex and cleft type on tooth agenesis.

**Results**: The most common cleft type was cleft lip and palate left (CL+ PUL) (n=72; 39.3%) and it was more frequently observed in men (44.3%) compared to women (30.9%). However, the association between cleft type and sex did not meet the significance level (p=0.114). Overall, tooth agenesis was found in 96 cases (52.5%), but still, the difference was not statistically significant, thus the relation between cleft type and tooth agenesis is considered weak (p=0.065). Additionally, sex was not associated with the prevalence of tooth agenesis (p=0.343), while the lateral incisor of the upper left quadrant was the most frequently missing tooth (29.5%), strongly depending on cleft type (p<0.001).

**Conclusions**: CL+ PUL was the most prevalent cleft type, while the most common missing tooth was the upper left lateral incisor. However, there is no significant correlation between tooth agenesis, different types of orofacial clefts and sex.

## 4. Differential diagnosis of ankylosis and primary failure of eruption

Kalliopi Siotou, **Isidora Christopoulou***, Maria Georgaki, Apostolos I. Tsolakis
*National and Kapodistrian University of Athens.

**Aim**: The normal eruptive process requires the execution of a sequence that must be coordinated so as to let the teeth erupt properly in the oral cavity. This sequence could be disturbed by mechanical obstacles, systemic or syndromic disorders and conditions like ankylosis or primary failure of eruption. The aim of this study is to underline the characteristics of primary failure of eruption and to point out the differential diagnosis between ankylosis and other causes of failure of eruption.

**Materials & Method**: A 15year old boy sought treatment at the Orthodontic Clinic of the National and Kapodistrian University of Athens, having been refused treatment, due to the complexity of the incidence, from many private orthodontic clinics. The evaluation of the patient included clinical and radiographic examination.
**Results**: The radiographic examination revealed failure of eruption of the first permanent mandibular molars bilaterally. After the extraction of the primary molars and any other obstacle, the teeth continued to remain unerupted. The CBCT revealed the absence of evidence of ankylosis. The primary failure of eruption was another possible explanation for this condition, but the patient has not undergone any genetic testing to confirm or reject this possibility.
**Conclusions**: Primary failure of eruption is a rare condition that can be justified only genetically. It has some characteristics that could predispose for its existence, but differential diagnosis from ankylosis and other conditions are deemed necessary.

## 5. Accuracy of interproximal enamel reduction during clear aligner treatment

**De Simone Antonella**,* Nucci Ludovica, Carrozza Domenico, Correra Antonia, Grassia Vincenzo
* Orthodontic Program, Multidisciplinary Department of Medical-Surgical and Dental Specialties, University of Campania Luigi Vanvitelli, Naples, Italy
**Aim**: The aim of the present study was to compare the accuracy of the actual space obtained through
interproximal enamel reduction (IPR) compared to the amount of IPR planned through the digital setup during clear aligner treatment (CAT).
**Material & Method**: A total of 10 clinicians were randomly recruited using the Doctor Locator by Align Technology (California). For each clinician, four consecutive patients treated with CAT and manual stripping were selected for a total of 40 subjects and 80 dental arches. For each patient, the amount of planned IPR and the amount of actual IPR performed were recorded. Each arch was considered individually. For each arch, the mesio- distal tooth measurements were obtained from second to second premolars.
**Results**: No systematic measurement errors were identified. In 25 cases, stripping was planned and performed in both arches; in 4 cases only in the upper arch and in the remaining 7 cases only in the lower arch. The difference between planned IPR and performed IPR was on average 0.55 mm (SD, 0.67; P = 0.022) in the upper arch and 0.82 mm (SD, 0.84; P = 0.026) in the lower arch. The accuracy of IPR in the upper arch was estimated to be 44.95% for the upper arch and 37.02% for the lower arch.
**Conclusions**: Overall, this study showed that the amount of enamel removed in vivo did not correspond with the amount of IPR planned. In most cases, the performed IPR amount was lower than planned. When considering the actual amount in millimeter, these differences may not be considered clinically relevant.

## 6. Reliability of measurements between conventional casts, laser scanned casts and intraoral scanning

**Dr. Ahmed Elkalza**[1]
[1] Assistant professor of Orthodontics, Alexandria University, Egypt
The aim of this study was to compare tooth measurements obtained by two

differently acquired digital model and conventional plaster cast measurements.
**Materials & Methods**: This study comprised 40 patients. Digital casts were obtained by two methods: Intraoral scanning by carestream intraoral scanner CS3600 powder free and model scanning by cast scanner Sirona InEos X5 scanner. Three study groups were obtained; Group 1: conventional dental casts, group 2: digital casts obtained with powder free intraoral scanning and group 3: digital casts obtained by cast scanner. Inter-canine and intermolar widths in addition to individual tooth measurements were made using Viewbox program for digital casts and digital caliper for the plaster cast.
**Results**: No statistically significant difference between three groups regarding all measurements had been found.
Conclusion: This study confirms that intraoral and model scanning are accurate and reliable as plaster casts poured into alginate impressions.

## 7. Ankylosed permanent molars and their effect on facial developement

**Zehava Geller Fishman**, Adrian Becker, Stella Chaushu
Department of Orthodontic, Hebrew University-Hadassah School of Dental Medicine, Jerusalem, Israel
**Aim**: Permanent molar ankylosis is a rare phenomenon, in which the affected tooth occupies an infraoccluded position in the dental arch or do not emerge into the oral cavity, limiting the involved alveolar bone development and leading to asymmetric dental occlusal relationship. However, the influence of this asymmetry on facial development gained no attention in the literature. The aim of the present pilot study was to assess whether unilateral molar ankylosis may lead not only to dentoalveolar asymmetry but also to facial asymmetry. Patients and methods: 14 healthy patients (9 males, 5 females, mean age 12.9 years) with unilateral molar ankylosis were recruited to this retrospective study. The initial extra-oral and intra-oral photos were assessed for facial and dentoalveolar asymmetry, by clinical judgment and the following measurements: the amount of chin deviation, vertical height differences between the gonial angles, the presence of occlusal canting. The differences between the ramal and condylar heights were measured on panoramic views.
**Results**: 8 subjects showed evident clinical facial asymmetry and at least 3 positive values of facial, skeletal and dentoalveolar asymmetry measurements (i.e more than 3% difference between affected side and contralateral and/or chin deviation and/or dentoalveolar occlusal cant).
**Conclusion**: More than half of the patients (57.1%) with unilateral molar ankylosis showed varied degrees of facial asymmetry and dentoalveolar occlusal cant. These findings should be considered when defining the occlusal and esthetic treatment goals and its optimal timing.

## 8. Casein phosphopeptide and amorphous calcium phosphate in sustained release delivery system: effect on oral biofilm (in vitro study)

**Gkeka Olga**[1,2], Sionov Vogt Ronit [2], Friedman Michael[3], Steinberg Doron[2], Shalish Miriam [1]
[1] Department of Orthodontics, [2] Biofilm Research Laboratory Institute of Dental Sciences, [3] School of Pharmacy, The Hebrew University- Hadassah School of Dental Medicine, Jerusalem, Israel

**Aim**: The aim of this study was to evaluate the in vitro antibacterial effect of pure casein phosphopeptide (CPP) and amorphous calcium phosphate (ACP) incorporated in a sustained release varnish applied on PVC pieces of orthodontic retainers.
**Materials & Methods**: ACP, CPP and placebo varnishes were applied on sterile PVC pieces. The coated pieces were incubated daily in the presence or absence of Streptococcus mutans for seven days. Metabolic MTT assay was performed to evaluate the percentage of bacterial biofilm on the coated PVC pieces. Coated PVC was also placed daily on BHI agar plates seeded with S. mutans followed by an overnight incubation at 37°C to evaluate the zone of inhibition.
**Results**: MTT assay of the separate ACP and CPP varnishes revealed a decrease in metabolic activity after the first day of exposure to S. mutans: 61.9% for ACP and 49.6% for CPP compared to placebo. On the fourth day, the vitality increased to 121% for ACP and 115% for CPP. On the seventh day, ACP showed 143% bacterial vitality and CPP 173%. The coated PVCs on agar plates did not show any inhibition zone when tested for seven consecutive days.
**Conclusions**: We observed a slight antibacterial activity for CPP and ACP when applied separately, after the first day of exposure. Later there was a significant increase in the bacterial metabolic level, suggesting that the antibacterial effect of the varnish markedly declined upon time. Further studies are required to optimize the sustained release varnish.

## 9. Case report of a patient with unilateral cleft lip and palate: the orthodontic approach

**Kathopoulis Ilias, DDS, MDSc**, Kathopoulis Michail, Student of Dental School, European University Cyprus
**Introduction**: Cleft Lip and Palate is the second most common congenital anomaly, affecting the growth of the maxilla. The severity of the defect determines the dentofacial deformities, such as maxillary hypoplasia, nasal floor perforation, crossbites, and impactions or absences of teeth.
Case report: A six-year-old female was presented with unilateral cleft lip and palate, Angle Class I with Class III tendency, anterior crossbite, impacted 22, ectopic 12 and lateral mandibular shift. After palatal suturing and lip reconstruction, the patient came to our practice for comprehensive orthodontics.
**Conclusion**: With the use of a Rapid Palatal Expander and fixed orthodontic appliances (braces), the crossbite was corrected, and space was created for the alignment of the impacted and ectopic laterals. Due to the location of the cleft, bone grafting was not needed. In addition, the anteroposterior and sagittal deformities were corrected, a stable and balanced occlusion was achieved, and the midline asymmetry was fixed. The final nose and lip plastic surgery can take place after the completion of the patient's growth.

## 10. Physioplastic changes of the face after deep bite correction: a case report

**Dr. Harris Krikonis**[1]
[1]Private Practice
**Aim**: This case intends to show the morphological changes of the face after deep bite correction. The fact that the patient was a teenager emphasizes

the importance of proper timing for maximizing the pro aging effects of orthodontic treatment.
**Case**: An eleven-year-old boy in late mixed dentition presented in our office. He was diagnosed with Class I skeletal and dental malocclusion. His upper and lower anterior teeth had severe crowding. He had a moderate deep bite with hypodivergent skeletal pattern and retroclined upper and lower incisors.
**Materials & Methods**: Patient had a two year non extraction treatment with fully-banded orthodontic appliances. Cephalometric analysis and photographic evaluation shows increase of the lower anterior face height a straight profile and proper angulation of the upper and lower incisors.
**Results**: Patient's deep bite correction and proper incisor angulation had a profound effect in the overall facial esthetics. Significant changes in the submental fold, the nasolabial angle and the lip fullness are being documented.
**Conclusions**: The correction of a deep bite with natural means is a unique potential of orthodontic treatment and has long lasting effects in the facial appearance.

## 11. Oligodontia: treatment planning and multidisciplinary approach: report of two cases

**Manoukakis T.**,[1] Trifonidou L.,[2] Kotsiomiti E.,[3] Manoukakis I.,[4]
[1] 5th Year Dental Student, MUS [2] Associate Professor Department of Prosthetic Dentistry, AUTH [3] Dentist, Netherlands, [4] Specialist Orthodontist Private Practice, Greece
In oligodontia cases (congenital missing of 6 or more teeth), the multidisciplinary approach is considered a complete treatment approach when it creates favorable circumstances for development of craniofacial structures as a base for future prosthetic rehabilitation and consequently fulfills the direct biological, functional, aesthetical and social needs of the patient especially in the vulnerable age of puberty.
Orthodontics aims to guide the development of the craniofacial structures, alignment of existing teeth and maintenance of the existing spaces for the needs of the future prosthetic rehabilitation while Prosthetics aims to cover the functional (mastication and speech) and esthetic (social acceptance, self-esteem) needs of the young patient.
This presentation aims to highlight the philosophy and rationale behind the treatment planning in two young children, a 8-year-old female (17 permanent teeth absent) and a 10-year-old male (10 permanent teeth absent).The treatment plan comprised two phases:
A. Orthodontic and speech therapy aimed at overbite and anterior open bite adjustment, as well as tongue position improvement; and
B. Prosthetic treatment by insertion of removable temporary partial dentures.
**Conclusion**: The multidisciplinary treatment involving orthodontics, speech and prosthetic therapies have re-established the masticatory function and aesthetics, allowing the patient to achieve greater self-esteem and better social acceptance.

## 12. "Pseudo-palatal" impacted canines and their diagnostic features

Vryonidou Mikaela, **Nucci Ludovica***, Dekel Eyal, Perillo Letizia, Chaushu Stella
*Orthodontic Program, Multidisciplinary Department of Medical-Surgical

and Dental Specialties, University of Campania Luigi Vanvitelli, Naples, Italy

**Aim**: "Pseudo-palatal" canine impaction occurs when the canines lie between central and lateral incisors' roots, the tip of the canine is palatal to central incisor and part of the crown buccal to lateral incisor. Our aim is to provide clinical and radiographic clues for correct diagnosis and treatment planning.
**Materials & Method**: The sample consisted of 27 cases. Control group of normally erupted canines was taken from previous study. Clinical evaluation was performed on photos. CBCTs were used for angular measurements of central, lateral incisors, first premolars and assessment of resorption of adjacent roots. Panoramic views served to assess the angulation of central and lateral incisors to midline and the angle between the two incisors. Lateral cephalometric views served to evaluate buccolingual inclination of central incisors. Statistics included paired t, Wilcoxon signed rank and McNemar tests.
**Results**: Pseudo-palatal canines were associated with palatal displacement and distal tipping of lateral incisors' roots, mesiolabial rotation of lateral incisors' crowns and labial displacement of central incisors' roots. The position of the first premolars was not affected. The risk for root resorption was not significantly increased.
**Conclusions**: Differential position of adjacent teeth is pathognomonic for diagnosis. The findings will provide clinical and radiographical clues and assist in planning efficient treatment strategy with minimal side effects.

## 13. Non-surgical correction of a class iii malocclusion in an adolescent by buccal shelf miniscrew – assisted dentition distalization: a 1-year follow-up

Nikolaos Karpitsaris[1], **Petros Papaefthymiou**[2], Zeynep Ahu Acar 3
[1] Private practice, Amsterdam, Netherlands,
[2] Marmara University, School of Dentistry, Department of Orthodontics, Istanbul, Turkey
[3] Professor, Marmara University, School of Dentistry, Department of Orthodontics, Istanbul, Turkey

**Aim**: Skeletal Class III malocclusion, presents complex characteristics regarding diagnosis and treatment planning, affecting not only the oral cavity but the whole craniofacial complex. This case report aims to describe a treatment method for a 16-year-old female patient with a Class III malocclusion using mandibular skeletal anchorage, with a 1-year follow-up.
**Materials & Method**: A-16-year old female patient had a skeletal Class III malocclusion, protrusive mandible, anterior crossbite, and a deviated midline. The treatment included the use of fixed appliances and bilaterally inserted miniscrews in the mandibular buccal shelf region, which were incorporated for the en-masse distalization of the mandibular arch. Pre-treatment, during-treatment, post-treatment, and 1-year follow-up records are shown.
**Results**: The anterior negative overjet, the deviated midline, and the Class III molar and canine relationships were corrected. The ANB angle increased by 2 degrees, and the mandibular plane angle increased by 4 degrees. The patient's facial profile was improved, ideal occlusal relationships were achieved, and the treatment outcome was stable after 1 year of retention.
**Conclusions**: These results suggest that the application of miniscrews in the mandibular buccal shelf region combined with fixed appliances could provide an efficient approach and a stable outcome for Class III camouflage treatment.

## 14. Intrauterine growth restriction affects bone mineral density of the mandible and the condyle in growing rats.

**Aliki Rontogianni**[1], Ismene Dontas[2], Demetrios Halazonitis[1], Pavlos Lelovas[2], Apostolos I.Tsolakis[1]
[1]Department of Orthodontics, School of dentistry, University of Athens, Greece
[2]Laboratory for Research of the Musculoskeletal System, School of Medicine, University of Athens, Greece

**Introduction**: Intrauterine growth restriction (IUGR) has been associated with increased prenatal and postnatal morbidity and mortality while also linked with variety of maternal-fetal pathological conditions. The present study investigates the effect of IUGR on the quality of the mandibular and condylar bone and the density of the mandible and tibia of growing rats.

**Materials & Methods**: Twelve male rats were born IUGR by mothers sustaining 50% food restriction during pregnancy. Twelve control male rats were born by mothers fed ad libitum. Dual-energy X-ray absorptiometry (DEXA) of the tibia, proximal tibial metaphysis and the mandible, biochemical markers, histology and histomorphometrical analysis on the mandibular and subchondral bone of the condyle were performed.

**Results**: IUGR affected Bone Mineral Density (BMD) of long bones significantly ($p<0.005$), even though a standard diet was available ad libitum to the offspring. BMD of the mandibular bone was also affected significantly in IUGR-born rats compared to the Controls in the antigonial notch was $p<0.0005$ and at the most inferior point of the mandibular symphysis was ($p=0.003$). IUGR rats had significantly lower osteocalcin values ($p=0.021$) and phosphorus ($p=0.028$) but not 25-OH vitamin D ($p=0.352$). Bone area percentage in the mandible was significantly lower (51.21±5.54) in IUGR compared to controls (66.00±15.49) and for subchondral bone of the condyle for IUGR (47.01±6.82) compared to controls (68.27±13.37). IUGR had a significant reduction in the fibrous layer but not the proliferating layer, with the hypertrophic layer significantly increased.

**Conclusion**: Maternal restricted nutrition during gestation can affect bone density of the mandible and the tibia of the offspring.

## 15. Oral health related quality of life with orthodontic aligners: a prospective pilot study

**Panagiotis Roulias**[1], Gerassimos Angelopoulos[2], Maria Ioulia Mylonopoulou[3], Iosif Sifakakis[4]
[1]Postgraduate student, Department of Orthodontics, National and Kapodistrian University of Athens, Greece
[2] Research associate, Department of Orthodontics, National and Kapodistrian University of Athens, Greece
[3] Orthodontist, private practice
[4] Assist. Professor, Department of Orthodontics, National and Kapodistrian University of Athens, Greece

**Aim**: The aim of this study was to estimate the patients' Oral Health Related Quality of Life (OHRQoL) and its association with anxiety during the first month of orthodontic treatment with aligners.

**Material & Methods**: Patients were asked to answer an OHRQoL questionnaire at the beginning of the treatment (Day 0), after one day (Day 1), a week (Day 7) and a month of treatment (Day 30). The Greek version

of the adult form of State-Trate Anxiety Index (STAI) questionnaire was also distributed. Patients answered both STAI subscales (Y1 and Y2) at the Days 0 and 30. The data were statistically analyzed using non-parametric Wilcoxon signed-rank test with SAS® University Edition software [Cary, NC: SAS Institute Inc.].

**Results**: The ability for food intake was affected between Days 0 and 1, the presence of ulcers between Days 0 and 7 as well as discoloration of the teeth between Days 0 and 30. No statistical significant changes were observed in any STAI subscales between Days 0 and 30.

**Conclusions**: Orthodontic treatment with aligners may affect patient's OHRQoL during the first month, however it does not affect patients' anxiety.

## 16. Mini-implant assisted transverse expansion in a late adolescent and an adult: presentation of clinical cases

**Panagiotis Roulias**[1], Gerassimos Angelopoulos[2], Iosif Sifakakis[3]

[1]Postgraduate Student, Department of Orthodontics, National and Kapodistrian University of Athens

[2]Orthodontist, Research Associate, Department of Orthodontics, National and Kapodistrian University of Athens

[3]Assistant Professor, Department of Orthodontics, National and Kapodistrian University of Athens

**Aim**: The aim of this poster is to present clinical applications of Miniscrew Assisted Rapid Palatal Expansion (MARPE) in late adolescents and adults, and underline the system's indications.

**Material & Methods**: Two clinical cases treated with MARPE are presented. Both patients were in late adolescence and in adulthood, in need for maxillary transverse expansion. Two miniscrews were placed in the paramedian area, 2 mm lateral to the suture in the 1stpremolar area combined with hybrid hyrax appliance with bands placed on the first upper molars. The activation protocol was one activation per day.

**Results**: Both patients presented favorable results from the MARPE system application, which agree with the existing literature. The system appears to be indicated for palatal expansion in adult patients as an alternative to surgery. MARPE has the advantage to perform better midpalatal suture expansion results in young adults, it controls the labial tipping of the posterior teeth, reduces risk of causing fenestrations, and it may solve anchorage problems due to lack of posterior teeth.

**Conclusions**: MARPE is a reliable system applied to adult patients for transverse expansion of the midpalatal suture, overcoming the disadvantages of the typical tooth-borne Hyrax device.

## 17. Dental anomalies: ontogeny and evolutionary perspectives

**Tatiana Sella Tunis**[1,2,3], Ofer Sarne, Israel Hershkovitz, Aikaterini Maria Pavlidi, and Nir Shpack

[1]Department of Orthodontics, The Maurice and Gabriela Goldschleger School of Dental Medicine, Tel Aviv University, Ramat Aviv 69978, Israel;

[2]Department of Anatomy and Anthropology, Sackler Faculty of Medicine, Tel Aviv University, Ramat Aviv 69978, Israel;

3Dan David Center for Human Evolution and Biohistory Research, Shmunis Family Anthropology Institute, Sackler Faculty of Medicine, Tel Aviv University,

Ramat Aviv 69978, Israel

**Aim**: Combining evolutionary knowledge with medical knowledge about the cascade of events that lead to the development of dental anomalies may result in better dental diagnosis and treatment, since no pathological phenomenon is fully understood unless both the proximate and evolutionary causations are considered. The aim of this study was to determine whether the upper and lower jaw differ in their susceptibility to dental anomalies (type and prevalence).

**Materials & Methods**: Pretreatment records (photographs and radiographs) of 2,897 patients (41.4% males and 58.6% females) were utilized to detect dental anomalies. The dental anomalies studied were related to number, size and shape, position, and eruption. A Chi-square test was carried out to detect associations between dental anomalies, jaw, and sex.

**Results**: A total of 1,041 (36%) of the subjects manifested at least one dental anomaly. The prevalence of all dental anomalies was jaw dependent, greater in the maxilla, except for submerged and transmigrated teeth. The most frequently missing teeth were the maxillary lateral incisor (62.3%) and the mandibular second premolars (60.6%). The most frequent supernumerary teeth were the incisors in the maxilla (97%) and the first premolars in the mandible (43%).

**Conclusions**: Dental anomalies are more frequent in the maxilla and mainly involve the anterior teeth; in the mandible, however, it is the posterior teeth. These differences can be attributed to the evolutionary history of the jaws and their diverse development patterns.

## 18. Digital fixed retainer accuracy

**Shereef Shahen**
University of Campania Luigi Vanvitelli: Universita degli Studi della Campania Luigi Vanvitelli

**Aim**: To check the accuracy of casted digital fixed retainers.

**Materials & Methods**: 20 upper and lower digital models were imported in 3Shape Appliance Designer. Shell was created 0.6 mm thickness and path of insertion occluso-posterior. Then exported in STL for printing. Bed of nails supports were added without violating borders to support shell on base plate support to connect all of them preventing deformation. Printing was done by msla printer using resin cast material. Traditional casting was done using Ni-Cr casting alloy. Then the laser scan carried out for the casted retainer. Fitting surface was sandblasted to create mechanical retention. Coupling agent was used to create also chemical retention. 3D fully automated superimposition was done by Viewbox software to compare the digital retainer version fused to digital model with the bonded real-life retainer scan. Moreover, a comparison between the digital retainer version to the real-life casted version was performed to check the accuracy. After superimposition, the differences were produced in rainbow color coded from 0 to 1mm (blue is the best and red is the worst).

**Results**: Digital retainer to the casted version was in blue zone (near zero) while in non-fitting surface less than 0.1 mm. These differences were mainly detected at the supporting pin contacts with retainer, maybe due to finishing procedure. It was not clinically significant as it did not affect the fitting surface.

**Conclusions**: Digital retainer described seemed to be accurate and reliable for the routinely clinical use.

## 19. Accidentally ingested fixed orthodontic retainer: a management protocol and a case report

**Konstantina Tsironi**[1], Gerassimos Angelopoulos[2], Iosif Sifakakis[3]
Department of Orthodontics, National and Kapodistrian University of Athens
[1]Postgraduate Student,
[2]Orthodontist, Research Associate,
[3]Assistant Professor.

**Aim**: To report a case of an accidentally ingested fixed orthodontic retainer and to develop a protocol on managing these incidents.
**Materials & Method**: An 18.2-year-old boy accidentally ingested a 0.0215 twistflex retainer during lunch. The wire had been bonded on upper six anterior teeth 18 months ago.
Additionally, the electronic databases Pub Med, Scopus and Science Direct were searched, using a combination of the keywords: ingested, foreign bodies, orthodontic.
**Results**: The patient reported abdominal pain and nausea after the ingestion and was instructed to seek hospital emergency care. A posteroanterior chest x-ray revealed that the wire was located in the stomach and few hours later a new x-ray showed that it had moved to the colon. Dietary instructions were given. After 2 days the wire found its way through the small intestine to large intestine binded with fecal matter and was expelled.
The literature search revealed 118 results. 35 different cases have been reported, of which only 2 were related to swallowed/ingested orthodontic retainers. Both of them were related to removable retainers. A flow chart was created with all diagnostic steps for the management of these cases. Finally, suggestions are made to reduce the risk of accidental ingestion of fixed retainers.
**Conclusions**: The risk of accidental ingestion/aspiration of fixed retainers has received little attention. Proper management of swallowed/ingested orthodontic objects is crucial to the patients' health and safety.

## 20. Impact of orthodontic aligners on speech and other oral functions

**Vasoglou George**, Angelopoulos Gerassimos, Sifakakis Iosif
Department of Orthodontics, School of Dentistry, National and Kapodistrian University of Athens, Greece

**Aim**: To explore the impact of Invisalign aligners on oral function, experienced by patients and the speech disturbances, evaluated by professionals, during the initial treatment phase.
**Materials & Method**: Adult patients undergoing orthodontic treatment with aligners were asked to pronounce (repetitively thrice) 5 words and standardized short videos were taken for the evaluation of speech at different time-points. Speech clarity was evaluated by three investigators through a 5-point Likert Scale. Additionally, they filled out a validated health-related quality of life questionnaire (HRQL). Data where statistically analyzed through linear random effects models and F-tests.
**Results**: The level of pain (Q1) increases at the beginning of the treatment and gradually decreases after the first month. Difficulties in speech (Q3), swallowing (Q4), eating certain foods (Q6) and in everyday activities (Q11) as well as food pleasure (Q7), lip trauma (Q14) and bad taste (Q15) are also significantly associated with time as average scores increase right after

placement and decrease after 4 months of treatment. Some patients notice a subtle change in the color of their teeth after 3 months (Q17). Consonants /s/ and /z/ are mainly affected after placement of the appliance. Speech disturbances recover after 3 to 6 months.
**Conclusions**: Orthodontic treatment with aligners mildly affects oral functions and quality of life during the initial months of treatment.

## 21. Management of missing maxillary lateral incisors

**Vlasiadi Eleni**, Georgios Damanakis, Apostolos Tsolakis
School of Dentistry, National and Kapodistrian University of Athens,Athens,
**Aim**: The aim of the present study is to outlay the possible therapeutic procedures in patients with congenitally missing maxillary lateral incisors and the problems encountered in the management of this disorder.
**Materials & Method**: Three cases with congenitally missing maxillary lateral incisors will be presented; one with space closure with reshaping canines and building them up to simulate lateral incisors, one with space opening followed by implant placement and a novel mini-screw supported temporary prosthesis in a case with unilateral agenesis of an upper lateral incisor.
**Results**: In general, two possible solutions are available: orthodontic space closure using canines to replace the missing maxillary lateral incisors and creating adequate space to prosthetically replace the missing lateral incisors with various prosthetic options. Taking into consideration all the relevant factors, an individualized approach is necessary to achieve the best possible functional and aesthetic result for the patient. Skeletal base relationship, canine shape and size, overjet, overbite, severity of crowding, periodontal condition, facial esthetics and growth are some of the parameters that need to be taken into account when the treatment plan decision is being made.
**Conclusion**: Congenitally missing maxillary lateral incisors are a common occurrence, creating aesthetic as well as functional problems. In order to achieve an optimal occlusion and acceptable aesthetics, cooperation between the orthodontist and the restorative dentist is essential.

## 22. Mandibular coronoid process hypertrophy: diagnosis and 20-yr follow-up

**Fiori Adriana***, Nucci Ludovica, Salafia Simona Grazia Maria, Ciampa Elena, d'Apuzzo Fabrizia
* Orthodontic Program, Multidisciplinary Department of Medical-Surgical and Dental Specialties, University of Campania Luigi Vanvitelli, Naples, Italy
**Aim**: The coronoid process hypetrophy (CPH) consists in an abnormal volumetric increment of the mandibular coronoid process as this process grows gradually, the infratemporal space needed for rotation and translation of mandible is reduced, which results in reduction of the ranges of mouth opening and lateral excursion, limiting mouth opening. The purpose was to describe diagnosis and treatment with a 20-yr follow-up of a rare case of hypertrophy of coronoid processes with associated temporomandibular ankylosis.
**Material & Method**: A patient with CPH was firstly visited when he had a facial trauma at the age of 4 years. Then he was followed through clinical, functional, instrumental, bi-dimensional and three-dimensional radiological evaluations up to the age of 24.
A physical therapy was initiated at the age of 10 years to improve

the condition of the masticatory muscles avoiding further mandibular movement reduction, mainly in the mouth opening and at the age of 14 years Transcutaneous Electrical Nerve Stimulations (TENS) were performed to reduce muscle tension and a bite plane was deliver to control the parafunctional activity of the jaw in the night and self-control instruction for daytime habits.

**Results**: The early diagnosis was advisable to monitor and limit the progression of the CPH and consequent limited movements in the oral multifunction and the patients declined to perform any surgical intervention when adult. The future objective is to continue the monitoring over the years to avoid a detrimental progression of the medical condition through physical and functional therapies, waiting for patient consent to the surgery if requested.

**Conclusions**: Mandibular restriction is found in different diseases; thus, the formulation of a precise diagnosis is more difficult. Complementary exams for clarifying a clinical condition in doubt should be considered significant. Even when the diagnosis is conclusive, it is not always viable to make a recognized therapeutic procedure and a more conservative approach is required, provided that this is duly explained to the patient.

## 23. Can impaction of the maxillary canine be prevented? How and when

Gerassimos Angelopoulos[1], **Andreas Ergatoudes**[2], Chris Georgiou[2], Panagiotis Magdanis[2].
Department of Orthodontics, National and Kapodistrian University of Athens
[1]Orthodontist, Research Associate
[2]Undergraduate Student,

**Aim**: We aimed to review on how and when to intervene in order to prevent the impaction of maxillary canines and propose a novel approach to improve spontaneous canine eruption.

**Material & Methods**: The electronic databases Pub Med, Scopus and Science Direct were searched, using a combination of the keywords: canine impaction, prognosis, treatment, spontaneous eruption and these combinations produced a total of 1849 results, the titles and abstracts of which were then examined. Twenty-seven papers met the inclusion criteria. Four ways to prevent impaction have been identified and a novel approach is proposed through clinical cases.

**Results**: The position of the erupting canine is crucial for the autonomous eruption of the canines. Extraction of the deciduous canine, use of cervical pull headgear use of a rapid maxillary expander as an early interceptive approach, concomitant extraction of both the deciduous first molar and canine and combinations have been proposed.

We are presenting a two-step interceptive treatment when the tooth buds of canines and first bicuspids are proximal to each other, whereby we first extracted the deciduous first molars accelerating the eruption of the premolar and then the path of eruption of the canines spontaneously improved and the deciduous canines exfoliated. This approach needs to be further investigated.

**Conclusions**: It is possible to intervene, facilitating the autonomous eruption of ectopic canines and thus avoid impaction.

## 24. Cervical headgear therapy and sleep-related attributes

**Gratsia Sofia**[1], Cocos Alina [2], Matsangas Panagiotis[3], Shattuck Nita [3], Vastardis Heleni [1]
[1] School of Dentistry, National and Kapodistrian University of Athens, Athens, Greece
[2] Private practice, Athens, Greece
[3] Naval Postgraduate School, Monterey, CA, USA

**Aim**: The study aims were to assess a) the effect of the cervical headgear on sleep attributes (namely quantity/ quality), and b) whether compliance with this orthodontic appliance is associated with sleep-related issues.
Methods: The study protocol was based on a prospective longitudinal quasi-experimental design. Participants (N=26; 9 males; on average 12.4±1.68 years of age) were patients in the Orthodontic Clinic of the National and Kapodistrian University of Athens. All patients received treatment with cervical headgear having an embedded TheraMon microsensor. Sleep was assessed by wrist-worn actigraphy for 59±19 days. The Epworth Sleepiness Scale (ESS) was used to assess average daytime sleepiness whereas for insomnia symptoms we used the Athens Insomnia Scale (AIS). Oral health-related quality of life (OHRQoL) was assessed by the oral health impact profile (OHIP-14).
**Results**: Patients slept on average 7.35±0.42 hours/day. Compared to the lowest sleep duration recommended for their age group, patients had an average chronic sleep deficit of 1.4±0.49 hours/day. Only 7 (28%) of the patients, reached or exceeded the wear-time recommendation of 12 hours/day. Interestingly, higher OHIP-14 scores were correlated with fewer hours of wearing the headgear (rho=-0.382, p=0.066). However, mixed effects regression analysis showed that AIS scores did not differ among study phases (p = 0.267).
**Conclusion**: We did not identify any serious sleep-related issues stemming from cervical headgear wear. On the other hand, worse oral health was associated with increased average daytime sleepiness, increased severity of insomnia symptoms, and fewer hours of wearing the headgear.

## 25. Orthodontic management of skeletal class ii malocclusion with the invisalign mandibular advancement feature appliance: a case report

**Melina Koukou***, George Damanakis, Apostolos Tsolakis
*National and Kapodistrian University of Athens, Faculty of Dentistry, Athens, Greece

**Aim**: The purpose of this case report is to present the treatment of skeletal class II malocclusion due to mandibular retrognathia with the Invisalign Mandibular Advancement Feature Appliance, which is new to clinical practice.
**Materials & Method**: This case report describes the orthodontic management of a 12 year old male patient having skeletal Class II malocclusion due to mandibular retrognathia. Since the patient was in active growth stage, growth modification with the Invisalign Mandibular Advancement Feature Appliance was planned.
**Results**: At the end of the treatment there was a significant improvement in the patient's profile and facial esthetics. The overjet and overbite were corrected with a Class I canine relationship and a Class III molar relationship. The dental and facial midlines were in alignment.

**Conclusions**: The Invisalign Mandibular Advancement Feature Appliance appears to be successful in the treatment of Class II malocclusion with mandibular retrognathism in a growing patient. As with all functional appliances, the correction of the malocclusion is a result of both skeletal and dental effects and the Invisalign Mandibular Advancement Feature Appliance presents the advantage of producing less proclination of the lower incisors compared to other functional appliances.

## 26. Mini-screw implants as a temporary restoration for congenitally missing lateral incisors: a viable solution? – case presentation

**Kovlakidis Alexandros** [2], Karagiorgos Ioannis[1], Karlou Effrosyni[1], Tsolakis Apostolos[2], Damanakis George[3]
[1] Undergraduate student, Dental School, University of Athens, Greece
[2] Associate Professor, Department of Orthodontics, University of Athens, Greece
[3] Orthodontist, Ph.D, Clinical Assistant, Department of Orthodontics, University of Athens, Greece

**Aim**: To present the orthodontic treatment of a congenitally missing maxillary lateral incisor using a Mini Screw Implant (MSI) in a teenage patient. With a frequency of 1.91-3.6%, lateral incisors are amongst the most commonly missing teeth and their loss contributes to a variety of aesthetic, functional and social problems, especially in adolescents. The objective of treatment in such cases is not only aligning dental arches but also ensuring and maintaining the lateral space, using a Maryland, a removable dental appliance or, in our case, a Mini Screw Implant.

**Materials & Methods**: Case presentation of a 12 year old girl seeking orthodontic treatment. The patient exhibits agenesis of #12 as well as microdontia of #22, in a Class III background. Alignment and opening of lateral space were achieved using braces. Digital impressions were taken using an intraoral scanner, a surgical guide was 3D-printed and a Mini Screw Implant was placed. Finally, the restoration was complete with a composite build-up.

**Results**: After orthodontic treatment, the MSI combined with the composite build-up was used as a temporary restoration and remains functional up to date, until the patient reaches the appropriate age for a permanent solution.

**Conclusions**: The use of MSIs appears to be a promising choice in temporarily restoring missing lateral incisors. This method offers aesthetics and functionality in addition to significant benefits, such as the retention of the alveolar ridge's volume, the preservation of lateral space for a dental implant as well as ease of placement and removal, due to the absence of osseointegration.

## 27. Disturbances in oral and dental structures after childhood cancer therapy

Isidora Christopoulou*, Maria Georgaki, **Kalliopi Siotou**
*National and Kapodistrian University of Athens, Greece

**Aim**: Survivors of childhood cancer remain at risk of dental developmental abnormalities such as agenesis, dental hypoplasia, root stunting, and enamel defects associated with the treatment they have been submitted to. The aim of this study is, through a case report, to underline the side effects of cancer

treatment in children in the maxillofacial region.
**Materials & Methods**: A 13-year-old girl sought orthodontic treatment at the Department of Orthodontics in the University of Athens. Her medical report included rhabdomyosarcoma of visceral skull diagnosed at the age of 5. The cancer treatment included surgery, chemotherapy, and proton therapy.
**Results**: From the panoramic radiograph and the clinical examination, it was proven that the cancer treatment she had undergone, had affected all the maxillary teeth causing extremely short or even no roots and consequent tooth mobility. Regarding the mandibular teeth, only the second permanent molars had been affected with shortened roots, justified by the age in which the cancer was treated and the stage of tooth formation and mineralization. From the orthodontic perspective, the evaluation reported bilateral class II molar relationship, increased overjet, an impacted upper left canine and different inclinations in the lower incisors.
**Conclusions**: Our findings from this case report confirm that the maxillofacial region is being strongly affected after cancer therapy in early childhood, with intense dental and oral manifestations. More high-quality studies are needed to establish a dental protocol to treat properly these young patients.

## 28. Gingival recessions and periodontal status after 2-yr-retention post orthodontic treatment: clinical and digital evaluation

**Strangio Bruno M**,* Federico Felice, Rotolo Rossana P, Minervini Giuseppe, Nastri Livia
* Orthodontic Program, Multidisciplinary Department of Medical-Surgical and Dental Specialties, University of Campania Luigi Vanvitelli, Naples, Italy
**Aim**: To assess gingival recessions (GR) and periodontal health in patients previously treated with non-extraction orthodontic treatment and retention at a follow up of minimum 2 years after the end of treatment.
**Material & Method**: Data from patients aged between 16 and 35 years with a previous non-extraction orthodontic treatment and at least 2 years of retention and full orthodontic records (extra and intraoral photographs, lateral cephalograms and dental casts) before and after treatment were collected. The casts were digitalized using the 3Shape TRIOS® intraoral scanner and the Viewbox 4 software was used for the measurements. The following parameters were scored: inclination of the lower and upper incisors (IMPA and I^SN) and anterior crowding (Little index).
The included patients were recalled for a clinical periodontal follow up examination and the following parameters were evaluated: buccal and lingual GR (mm) of incisors and canines, bleeding of probing score, plaque score, gingival phenotype.
**Results**: The digital cast analysis showed a mean Little index of 7.78 (SD 5.83) and 1.39 (SD 0.79) respectively before and after treatment. The initial and final cephalometric analyses showed a I^SN of 103.53° and 105.78°(SD 7.21) and IMPA of 91.3°and 95.1°, respectively.
At the follow-up periodontal visits, the patients showed an overall low oral hygiene with bleeding at probing in 66.6% and plaque in the anterior area in 76.2% of patients. From the total examined 240 teeth of the frontal sextants, three patients had GR (from 1 to 6.5 mm): in the upper arch 2 at canines and 1 at central incisor, whereas in the lower arch 2 at central and 1 at lateral incisors.

The gingival phenotype was "thick" in 55% of cases. The lingual lingual-to-lingual retainers at follow-up were present in the 61.9% of patients while the others wear removable appliances.

**Conclusions**: Our results, within the limitations of the study, showed that a non-extraction orthodontic treatment performed with controlled forces and correct biomechanics, seems to not affect the development of buccal and lingual GR or the periodontal health after at least two years of retention.

**«The best e-poster will be awarded»**

# Congress Information

*Athina Room 7th MOIP/16th P.O.C.*

*Hera Room 7th MOIP/16th P.O.C.*



ΕΤΑΙΡΕΙΑ ΟΡΘΟΔΟΝΤΙΚΗΣ & ΓΝΑΘΟΠΡΟΣΩΠΙΚΗΣ ΜΕΛΕΤΗΣ & ΕΡΕΥΝΑΣ | GREEK ASSOCIATION FOR ORTHODONTIC STUDY & RESEARCH


WYNDHAM GRAND
WYNDHAM GRAND

## Congress Venue
The 7th MOIP / 16th P.O.C. will be hosted by Wyndham Grand Hotel, Meg. Alexandrou 2, 104 37 Athens, Greece, tel.: +30 21 6800 9900

## Congress Dates
Pre-Congress Seminar: Friday, September 3rd, 2021
Congress: Saturday, 4th and Sunday, September 5th 2021
Post-Congress Seminar: Sunday, September 5th 2021

## Congress Secretariat
Prior to the Congress and one month after that, all inquiries should be addressed to: EVEREST TRAVEL & CONGRESSES, 14-16 Lykourgou str, 10552 Athens, Tel. +30 210 3249242, Fax: +30 210 3242395, ext. 5220 e-mail: conference@everesttravel.gr. During the Congress the secretariat will be operating at the lobby of Wyndham Grand Hotel from 8:30 to 17:30 pm.

## Language
The official languages of the Congress will be English and Greek. Simultaneous translation will not be provided.

## Book of Abstracts
The book of abstracts containing all abstracts of free topic oral presentations and posters is contained in this issue of the Congress Programme.

## E - Poster Exhibition
E- Posters will be uploaded for the entire duration of the Congress and at the Congress site.

## Audiovisual Equipment
The Congress Hall is equipped with data video projector and screens. A reception desk for acceptance and checking of USB sticks will be located nearby the Secretariat. Speakers are kindly requested to hand out their material and test the projection during the coffee break prior to their respective presentation.

## Congress material
The attendees registered for the 7th MOIP / 16th P.O.C. will receive at the Congress Secretariat their name badge which should be worn at all times so that they can have access to the Congress and Exhibit Halls.

## Exhibition
A large exhibition of orthodontic products and services will be open adjacent to the Congress Hall area during the Congress. There will also be available a virtual exhibition at the Congress site.

## Cellural Telephones
The 7th MOIP / 16th POC is concerned with quality education and allowing the hall to be disrupted with personal communication devices is a disservice to your fellow professionals. Turn your cell phone off or on silent before entering the lecture hall. If you must use your cell phone, be courteous and leave the lecture hall first.

## Letter of invitation
Persons requiring an invitation letter in order to attend the Congress may write to the Congress Secretariat. This procedure aims in assisting participants who need to obtain a visa in permission to attend the Congress and should not be considered as an official invitation covering fees or other expenses.

## Photography and Recording
Photographing or recording of oral and poster presentations is not allowed. A professional photographer will document the main congress events and the photographs will be available for purchase after the congress from the organizing committee.

## Name Badges and Entry Tickets

Participants and accompanying persons are obliged to wear the official congress name badges at all congress events. An additional fee will be charged for reproduction of lost name badges. Entry tickets to social events should be shown upon entrance to each event.

## Non-smoking Policy

Smoking is prohibited in the congress and exhibition areas. Smoking is also prohibited indoors in public buildings and other places open to the public, except in designated smoking areas.

## Certificate of Attendance

All participants receive a certificate of attendance.

## Liability and Insurance

The organizers cannot be held responsible for any claim concerning liability, injury or damage to persons or properties, illness, non-appearance of speakers etc. Participants and exhibitors are, therefore, kindly requested to take out their own insurance. No additional claims will be accepted.

## Cancellation Policy for Registration

Submit your cancellation in writing to the secretariat via e-mail or via fax. Telephone cancellations will not be accepted. Your cancellation/refund request should include your name, registration confirmation number and the reason for the refund. All refund requests are subject to approval by the board of trustees of G.A.O.S.R. All approved refunds will be processed within thirty (30) days after the approval. Registration cancellations and registration fee refunds will not be processed on-site during the congress. Registration fees will be refunded to person who paid fees, by the same method of payment (i.e. credit card, wire transfer, etc.). In the case of a credit card payment, only to the same credit card used to pay fees.

- A 100% refund, less €50.00 Euros administrative fee, will be issued only with a "written cancellation request" received on or before 10.6.2021.
- A 50% refund, less €50.00 Euros administrative fee, will be issued only with a "written cancellation request" received on or before 15.8.2021.
- No refunds after 16.8.2021.
- No refunds for virtual attendance.
- In case of change in the attendance form, any difference in fees will be added or subtracted respectively.

In case of serious illness with the submission of pertinent proof will be approved on an individual base.

## Cancellation policy for Accommodation

Please contact the Congress Secretariat regarding your hotel's individual cancellation policy.

## Important Notices

The G.A.O.S.R. cannot be responsible for registration and housing materials lost in the mail or for the postmark on mailed Registration and / or Housing Forms. You may wish to send your completed form with payment via certified mail to guarantee delivery, especially if it sent close to the deadline date.
The G.A.O.S.R. is only responsible for the registration and / or housing materials after they are received. The G.A.O.S.R. cannot be responsible for incomplete faxes. The G.A.O.S.R.
encourages you to keep a date-stamped of your fax or date-stamped printout of your online registration form for your records.

## ATHENS, The capital city

You will have the chance to visit the oldest inhabited city in the world, the cradle of democracy and western civilization as we know it today, which begun as a small fortified village built on the top of Acropolis rock as far back as 3.000 years BC. Naturally, Athens is full of museums and archaeological sites of the outmost interest, and one can almost follow the glory that Athens had through a visit to Acropolis Museum, the Parthenon and the national Archeological Museum. From then on, Athens grew steadily to the very large city that it is today, boasting a population for the whole area of around 4,5 millions. Athens is also a cosmopolitan city that offers to visitors unlimited possibilities for excursions, sightseeing and nightlife.

## On arriving Athens

All international flights arrive at the Athens International Airport El. Venizelos which is located about 50 Km from congress venue.

## Passport & Visas

A valid passport is required for entering Greece for the non-EU citizens. An identify card is sufficient for the citizens of the EU member countries. Please consult the nearest Greek Consulate for specific details.

## Transportation

The sub-way connects several major points in Athens and additionally the public transportation is serviced by trolley buses, tram and buses. Airport bus serves every 20 minutes on a 24 hour basis. Taxis are easy to find. Cars for hire are available at the airport. The Congress Secretariat can also help you rent a car. Please visit the official website of the Athens international airport for more information on transportation and passenger
services: www.aia.gr

## Banks

Banking hours for the public are Monday to Thursday 8.00΄ to 14.00΄ and Friday 8.00΄ to 1.30΄. However, some centrally located banks provide "afternoon tourist services".

## Currency

Euro is the Greek currency.
The eight denominations of coins vary in size, colour and thickness according to their values, which are 1, 2, 5, 10, 20 and 50 cents or EUR 1 and EUR 2. One euro is divided into 100 cents. Bank notes are in denominations of 5, 10, 20, 50, 100, 200 and 500 Euros.

## Climate-Clothing

In September, Greece has a warm Mediterranean climate with an average temperature of 20o C and possible light showers. Light clothes are recommended but a sweater or jacket may occasionally be needed. Casual informal clothing is appropriate for all occasions.

## Power Supply

The power supply supply in Greece is 220 Volts/50 Hz. The plugs have 2 or 3 round pins similar to those in many European countries.

# PLACES TO VISIT

## Syntagma Square

(1.8 km from the venue hotel, buses E14/X14, 224, 732 or metro M3 from Evangelismos station – 15-20 minutes)

Syntagma Square is the most famous in Athens if not all of Greece, it is dominated by the imposing neoclassical Old Royal Palace, which has housed the Greek Parliament since 1935.

## Acropolis

(2 km from the venue hotel, 8 minutes by car or taxi depending on traffic or metro M3 from Evangelismos station to Syntagma Square then bus 230 – 30 minutes)

The Acropolis, or Sacred Rock, is synonymous with Athens. Streets around the Acropolis are pedestrian areas.

Contains the remains of several ancient buildings of great architectural and historic significance, the most famous being the Parthenon.

A UNESCO World Heritage site, this is a must to visit while in Athens.

## The Acropolis Museum

(2.4 km from the venue hotel, bus 550 or metro M3 from Evangelismos station, then M2 from Syntagma Square – 17-19 minutes)

Built during the 1990s and open since 2009, the modern Acropolis Museum was commissioned as the existing museum could no longer house the growing volume of archaeological treasures discovered on the site.

Its exhibits cover the period from the Greek Bronze Age to Roman and Byzantine Greece.

## National Archaeological Museum

(2.4 km from the venue hotel, bus 224 then metro M2 or M1 or bus 608, 622 from Evangelismos metro station– 30-40 minutes)

The National Archaeological Museum is one of the best in the world, housing artifacts from pre-history to late Antiquity with its Cycladic, Mycenaean and Egyptian collections. It has best collection from Ancient Greece anywhere in the world.

## Byzantine & Christian Museum

(1 km from the venue hotel, a 15-minute walk)

The Byzantine and Christian Museum, which is based in Athens, is one of Greece's national museums. Offers an impressive collection of Christian and Byzantine art. Exhibits are divided into ancient (4th to 15th century) and modern (15th to 20th century).

## Benaki Museum

(1.2 km from the venue hotel, 16 minutes on foot)
The Benaki Museum has several sites, but the main one is the former Benaki family mansion in central Athens. It houses a diverse collection, including Islamic art from across the Near East, Chinese and pre-Colombian art, as well as a particularly complete and important collection of Greek artifacts from ancient times to the early 20th century.

## Panathenaic Stadium

(15 min walk distance from the venue hotel)
The Panathenaic Stadium, also known as the Kallimarmaro (meaning the "beautifully marbled"), is a multi-purpose stadium used for several events and athletics in Athens. The Stadium hosted the first modern Olympic Games in 1896.
Reconstructed from the remains of an ancient Greek stadium, the Panathenaic is the only stadium in the world built entirely by marble and is one of the oldest in the world

## Athens Concert Hall

(10 min walk from venue hotel)
The Hall was inaugurated in 1991 with two halls. Since then it has been augmented with two more halls and now has a total of four: two large and two smaller ones. The Hall has optimal facilities for opera performances, and some operas are presented every season.

## COVID -19 GENERAL INSTRUCTIONS

- All participants must be either vaccinated (demonstration of full vaccination certificate) or have performed rapid test or RT-PCR test one day before their arrival in the Congress venue (demonstration of negative result) or obtain the EU Digital Covid -19 Certificate
- The use of a mask and the compliance with hygiene rules are mandatory for all participants entering the congress venue.
- The admission of delegates and speakers in the congress room will be performed through electronic scanning of the delegate card. The maximum number of persons admitted in the congress room will depend on the hygiene protocols against COVID-19. Standing in the room is not allowed.
- Registration, the issuance of congress badge, the congress program, as well as certificates of attendance will be available in an electronic form.
- In case a participant presents symptoms related to COVID - 19, the Congress Secretariat should be informed in order to allow admission to the specially designed isolation area for COVID-19 cases.
- All participants must fully comply with the general hygiene recommendations for COVID - 19 (such as frequent hand washing, mask usage, distance keeping etc).

We are continuously reviewing and updating our approach to follow the latest government and health guidelines.
For any updates, please visit the congress website regularly ( https://moip2021.com/ )

It is strongly recommended that all visitors download the Visit Greece app (GDPR compliant) for free, prior their arrival in Greece. The PLF can also be found on the Visit Greece app and at travel.gov.gr
Protocol for Arrivals in Greece
https://travel.gov.gr/#/

*Exhibition of Dental and Orthodontic Products & Services*

ΕΤΑΙΡΕΙΑ ΟΡΘΟΔΟΝΤΙΚΗΣ & ΓΝΑΘΟΠΡΟΣΩΠΙΚΗΣ ΜΕΛΕΤΗΣ & ΕΡΕΥΝΑΣ | GREEK ASSOCIATION FOR ORTHODONTIC STUDY & RESEARCH

**Exhibit Hall**

# Floor plan of the exhibit hall

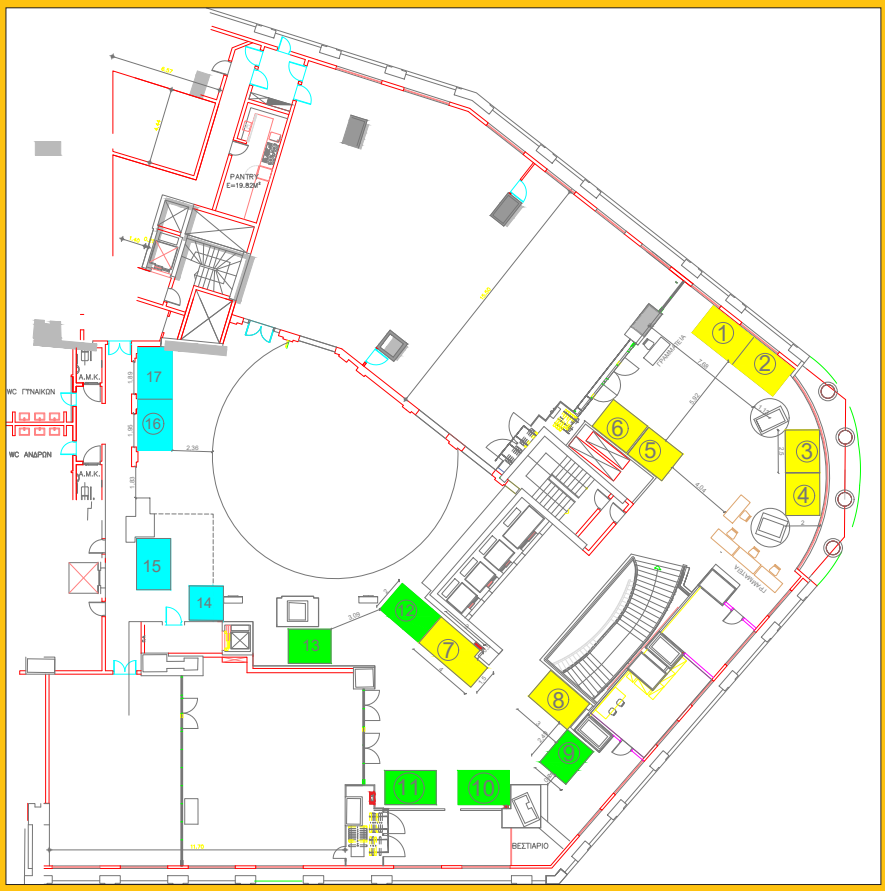


| BOOTH | EXHIBITORS |
|---|---|
| 1 | INVISALIGN - Itero |
| 2 | MEMODENT A.E. |
| 3 | IOANNIS TSAPRAZIS SA - R.M.O. |
| 4 | ORTHO CENTER - K. ELEOTRIVIARI |
| 5 & 6 | UNIDENT- K. ΤΖΙΒΕΛΕΚΑΣ |
| 7 | M. VITSAROPOULOS |
| 8 & 9 | ORTHOSHOP E.E.-ROYAL ORTHODONTICS |
| 10 | VETTOS ORTHOLAB |
| 11 | FN ORTHODONTICS |
| 12 | ORTHO-EXPERT - I. MALOUTA |
| 13 | ORAL B |
| 14 | ABC KINITRON |
| 15 | DENTALCOM G. PAPAZOGLOU SA |
| 16 | ORTHOSMILE |
| 17 | UNISHAPE - K. ANTONIOU |

# EXIBITORS

| EXHIBITORS | BOOTH | ADDRESS | TEL. |
|---|---|---|---|
| INVISALIGN - Itero | 1 | Steliou Kazatzidi 47, Thesaloniki, 555 35, pperros@aligntech.com | 2314312147, 2313051505 |
| MEMODENT A.E. | 2 | Veranzerou 4, Athens, 106 77, dental@memodent.gr | 210-3304050 |
| IOANNIS TSAPRAZIS SA - R.M.O. | 3 | Michalakopoulou 157, Goudi 115 27, iris@tsaprazis.gr | 210-771 6416, 210-771 1100 |
| ORTHO CENTER - K. ELEOTRIVIARI | 4 | Apostoli 21-23, Chalkida, 34100, info@ortho-center.gr | 22210-204 10, 22210-854 50 |
| UNIDENT- K. ΤΖΙΒΕΛΕΚΑΣ | 5 & 6 | Grammou 40, Vrilissia 152 35, info@ktzivelekas.gr | 210 685 8070, 210 685 8099 |
| M. VITSAROPOULOS | 7 | Mesogion 348, Athens,153 41, info@vitsaropoulos.gr | 210-654 1340, 210-654 1618 |
| ORTHOSHOP E.E. ROYAL ORTHODONTICS | 8 & 9 | Sp. Davari 67, 19441, Koropi, info@orthoshop.gr | 2109958506, Fax: 2106043457 |
| VETTOS ORTHOLAB | 10 | Fidippidou info@ortholab.gr, Goudi, info@ortholab.gr | 210 52 30 152, Fax 210 52 36 888 |
| FN ORTHODONTICS | 11 | Tetrapoleos 2-8, Athens,11527, fn_orthodontics@yahoo.gr | 210-77 73373 |
| ORTHO-EXPERT - I. MALOUTA | 12 | Ilias 12, Patra, ortho-expert@hotmail.com | 2610240609 |
| ORAL B | 13 | Dervenakion 8, Dafni 17235, , boura.j@gmail.com | 210-9287700, 210-9287333 |
| ABC KINITRON | 14 | Kafkasou 163, Athens, 113 64, info@abckinitron.com | 210 8650583 |
| DENTALCOM G. PAPAZOGLOU SA | 15 | Kariofili 24, Athens, 115 27, sales@dentalcom.gr | 210-7775021 210-7775110 |
| ORTHOSMILE | 16 | 79 Marathons Av., Anixi, 14569, ortho-smile@live.com | 210-8145775 |
| UNISHAPE - K. ANTONIOU | 17 | Monastiriou 183, Thessaloniki, 546 27, unikostas@gmail.com | 2310-542917 |


# ACKNOWLEDGEMENTS

The president and the organizing committee wish to express their appreciation to all the Exhibitors that contributed to this congress. Special thanks go to FN Orthodontics & Invisalign iTero for the sponsoring of the Congress.

# Εκδόσεις ΕΟΓΜΕ

# BOARD OF DIRECTORS

## GREEK ASSOCIATION FOR ORTHODONTIC STUDY AND RESEARCH

| | |
|---|---|
| President: | Effie Basdra |
| Vice-president: | Gerassimos Angelopoulos |
| Secretary: | Vasileios Stathopoulos |
| Treasurer: | Maria Exarchou |
| Public Relations: | Aliki Rontogianni |
| Subst. Members: | Dimitrios Konstantonis, Theodoros Raisakis, Magdalini Kiokpasoglou |

## CYPRUS ORTHODONTIC SOCIETY

| | |
|---|---|
| President: | Georgia Sofroniou |
| Secretary General: | Christodoulos Laspos |
| President elect: | Abraam Kyriakidis |
| Treasurer: | Skylouriotou Marilena |
| Member: | Efstathiou Stathis |
| Past president: | Giagos Giagou |

## GREEK ORTHODONTIC ALIGNER SOCIETY

| | |
|---|---|
| President: | Georgios Damanakis |
| Vice-president: | Gerassimos Angelopoulos |
| Secretary: | Aikaterini Douma |
| Treasurer: | Evangelia Stamou |
| Public Relations: | Georgia Theodoridi |

Director of the Scientific Magazine: Dimitrios Papageorgiou
Director of Scientific Meetings: Ioanna Gidarakou

## GREEK SOCIETY OF LINGUAL ORTODONTICS

| | |
|---|---|
| President: | Stefanos Karakousoglou |
| Vice-president: | Elias Kathopoulis |
| Secretary: | Konstantinos Markou |
| Treasurer: | Christos Lefas |

## CONGRESS PRESIDENT

Demetrios Halazonetis

## ORGANIZING COMMITTEE COORDINATORS

Gerassimos Angelopoulos, Vasileios Stathopoulos

## ORGANIZING COMMITTEE

Georgios Damanakis, Stathis Efstathiou, Lina Theodorakopoulou, Eirini Kapogianni, Stefanos Karakousoglou, Despoina Marina Koutsoumpou, Marina Laskari, Ioannis Lyros, Michail Panagiotis Maroulakos, Georgia Bonataki, Boulouchou Ourania, Theodora Nakou, Panagiota Papazoglou, Ioanna Pavlou, Maria Rizou, Aliki Rontogianni, Iosif Sifakakis, Georgia Sofroniou, Nikolaos Spyropoulos, Foteini Tsingene

## SCIENTIFIC COMMITTEE

Effie K. Basdra, Angelos Metaxas, Moshos Papadopoulos